

# Application of low-level laser as auxiliary therapeutic of swelling areas caused by apical accidental extrusion of sodium hypochlorite: case report

Aplicação do laser de baixa intensidade como auxiliar terapêutico em áreas de edema causadas por extrusão acidental de hipoclorito de sódio: relato de caso

Key F. S. PEREIRA<sup>1</sup>, Maria L. S. MELLO<sup>2</sup>, Pedro G. SILVA<sup>1</sup>, Fabio N. ARASHIRO<sup>1</sup>, Carlos ESTRELA<sup>3</sup>

1 - DDS, MSc, PhD. Professors of Endodontics and Radiology, School of Dentistry, Federal University of Mato Grosso do Sul, MS, Brazil.

2 - DDS. Undergraduate student, School of Dentistry, Federal University of Mato Grosso do Sul, MS, Brazil.

3 - DDS, MSc, PhD. Professor Stomatologic Science Department, School of Dentistry, Federal University of Goiás GO, Brazil.

## ABSTRACT

**Aim:** To discuss an apical accidental extrusion of 2.5% sodium hypochlorite (NaOCl) with assistance of low-level laser. **Case Report:** A 39-year-old female was referred to the undergraduate clinic and during root canal preparation (RCP) reported an immediate burning sensation, which was accompanied by an acute and severe pain. After 3 hours, the patient returned with persistent spontaneous and severe pain in the area of the maxillary incisor and pronounced swelling in her upper lip. The diagnosis hypothesis was accident with extrusion of NaOCl beyond of apex root. The patient immediately received a single oral dose of 8 mg of corticosteroids, and also was prescribed amoxicilin,

and anti-inflammatory. To assist the control of inflammation, low level laser therapy was performed. **Results:** The patient returned 18 hours after the first appointment and the pain and swelling gradually decreased, and although there was extensive ecchymosis, no skin necrosis was observed. After 4 days, the patient presented no pain and the swelling area had total remission on day 11. The 17 months follow-up showed clinical aspect with normal appearance. **Conclusions:** The therapy with antibiotics, anti-inflammatory and LLLT for severe tissue damage caused by NaOCl reduced the severe manifestations of pain and edema.

**KEYWORDS:** Endodontics, Root canal irrigants, Sodium hypochlorite, Accident prevention.

## INTRODUCTION

Root canal preparation (RCP) is essential to disinfection process in infected root canal. This phase is constituted of various steps, although they are inter-dependent and should be considered simultaneously and as synchronized procedures. Shaping is performed by instrumentation in complex anatomical areas. Irrigant solutions are indispensable to aid the debridement process<sup>1</sup>.

During RCP, irrigants should facilitate the removal of debris and microorganisms via washing. A root canal irrigant is applied to obtain lubrication, penetrate inside root canal ramifications and should not damage dentine and apical periodontal tissues<sup>2,3</sup>. Sodium hypochlorite can dissolve organic tissues and the organic components of the smear layer. These skills enable the hypochlorite to kill root canal pathogens organized in biofilms and dentinal tubules because hypochlorite is considered to be the main endodontic irrigant in root canal treatments<sup>2-5</sup>. Zehnder<sup>2</sup> reported that the root canal irrigants exhibit a broad antimicrobial spectrum and demonstrate efficacy against anaerobic and facultative microorganisms, which are organized in biofilms, dissolve necrotic pulp tissue remnants, inactivate endotoxin, prevent the formation of a smear layer during instrumentation or dissolve the latter once it has been formed. Furthermore, as endodontic irrigants come into contact with vital

tissues, they should systemically become nontoxic and noncaustic to periodontal tissues and have little potential to induce an anaphylactic reaction.

Sodium hypochlorite is a strong base which affects cytoplasmic membrane integrity. Its antimicrobial mechanism of action develops by oxidation which promotes irreversible enzymatic inhibition of bacteria and replaces hydrogen with chlorine. The action on enzymatic sites promotes irreversible inactivation because of the presence of hydroxyl ions and chloramination. Tissues are dissolved during saponification, when destroys fatty acids and lipids, which leads to the formation of soap and glycerol<sup>5</sup>.

Sodium hypochlorite is the best known irrigants and used by dentists all over the world. It is available in concentrations between 0.5 to 5.25%, and its concentrations are directly proportional to its antimicrobial effect and tissue dissolution capacity and inversely proportional to its biological compatibility.<sup>5</sup> Thus, the inadequate concentration of sodium hypochlorite may cause tissue damage once it has a cytotoxic effect when in contact with vital tissues<sup>5-9</sup>.

These accidents may present severe complications including severe pain; ballooning or immediate edema in soft tissue; extension of edema to a large area of the face, such as the cheeks; periorbital ecchymosis on skin or mucosa as a result of profuse

interstitial bleeding; profuse intraoral bleeding directly from root canal; palatal mucosa necrosis; tissue necrosis; neurologic complications; paresthesia; allergy; chemical burn in eyes; dermatologic problems; and life-threatening airway obstruction<sup>10-23</sup>.

A little report has described the application of low-level laser therapy in accidents associated with sodium hypochlorite. This study discusses an apical accidental extrusion of 2.5% sodium hypochlorite treated with assistance of low-level laser.

### CASE REPORT

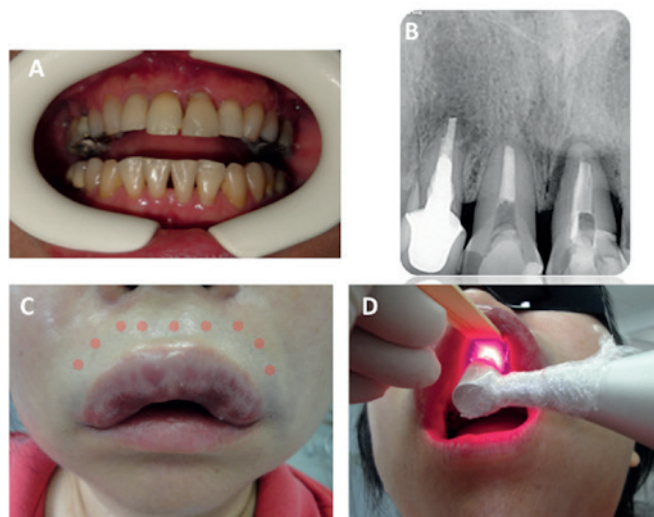
A 39-year-old female in good health was referred to the undergraduate clinic of School of Dentistry (Federal University of Mato Grosso do Sul, Campo Grande, MS, Brazil), for a root canal treatment (RCT). An intraoral examination revealed that the maxillary left central incisor was positive for both percussion and palpation (Figure 1A), and there was also a deep periodontal pocket in the buccal area. Radiographic images showed RCT behind apical limit, associated with secondary infection (Figure 1B). In addition to these aspects, it was verified the present of an endodontic-periodontal lesion.

The tooth was anesthetized with 2% lidocaine with 1:200,000 epinephrine (Alphacaine, DFL, Rio de Janeiro, Brazil), and the tooth was isolated using a rubber dam. The pulp cavity was accessed, and the root canal filling materials from the cervical and middle root canal thirds were removed using Gates-Glidden burs #2, 3 and 4 (Dentsply Maillefer, Ballaigues, Switzerland). Next, 2.5% NaOCl was delivered into the root canal, and hand K-files (Dentsply Maillefer, Ballaigues, Switzerland) were used to continue root canal filling materials remotion until apical foramen. The working length was determined as 1 mm from the root apex using a radiographic method. The root canal was prepared to K-file #80 using a crown-down and step-back techniques with a 2.5% sodium hypochlorite solution. The root canal was dried with paper points, and a calcium hydroxide paste (Ultracal, Ultradent, USA) was placed into the root canal. The tooth was temporized with a lightcuring flowable composite (FGM, Joinville, SC, Brazil).

During root canal preparation (RCP), the patient reported that she experienced an immediate burning sensation, which was accompanied by an acute and severe pain. When the undergraduate student was asked about the patient's report he explained that he had used supplemental infiltrations of anesthesia for pain control. He also reported using a side-delivery orifice irrigation needle and that he was not confident about the binding of the irrigation needle tip in the root canal.

After three hours, the patient returned to the undergraduate clinic with the chief complaint of persistent spontaneous and severe pain in the area of the maxillary incisor and pronounced swelling in her upper lip (Figure 1A, 1B). The patient immediately received a single oral dose of 8 mg of corticosteroids (Celestone EMS, Sigma Pharma, SP, Brazil). The tooth was accessed again and copious irrigation with sterile saline was performed. The root canal was left empty and sealed with a lightcuring flowable composite. Antibiotics (amoxicilin, GlaxoSmithKline, 500 mg, three times daily, over 6 consecutive days) and anti-inflammatory (Nimesulide, Aché Laboratórios Farmacêuticos S.A., 100 mg, twice daily dose over 6 consecutive days) were prescribed.

To assist the control of inflammation, low level laser thera-



**Figura 1** - Intraoral clinical aspect initial (A). The radiographic image demonstrates insufficient endodontic treatment and apical radiolucency (B). The initial presentation three hours after the accident, laser application extraoral scheme (C). Laser application at the buccal, and palatal periapical areas (D).

py (wavelength 808 nm, infrared, MMOptics, Brazil) was performed according to the manufacturer's instructions (power 60mW, 38 seconds/point, 70 J/cm<sup>2</sup> and energy 2,8J/point), in the buccal, palatal and swelling areas for three hours after the accident (Figure 1C, 1D) and when the patient returned to case control conditions (18 hours after the first appointment and 3, 6 and 11 days consequently). Furthermore, the patient received daily contacts to monitor her recovery. The pain and swelling gradually decreased, and although there was extensive ecchymosis, no skin necrosis was observed. After 4 days, the patient presented no pain and the swelling area had total remission on day 11. In clinical and radiographic follow-up after 17 months of accident, the clinical aspect of patient showed normal appearance, and the tooth was extract due the severity of endo-periodontal lesion, and now is waiting to rehabilitation with dental implant (Figure 2).

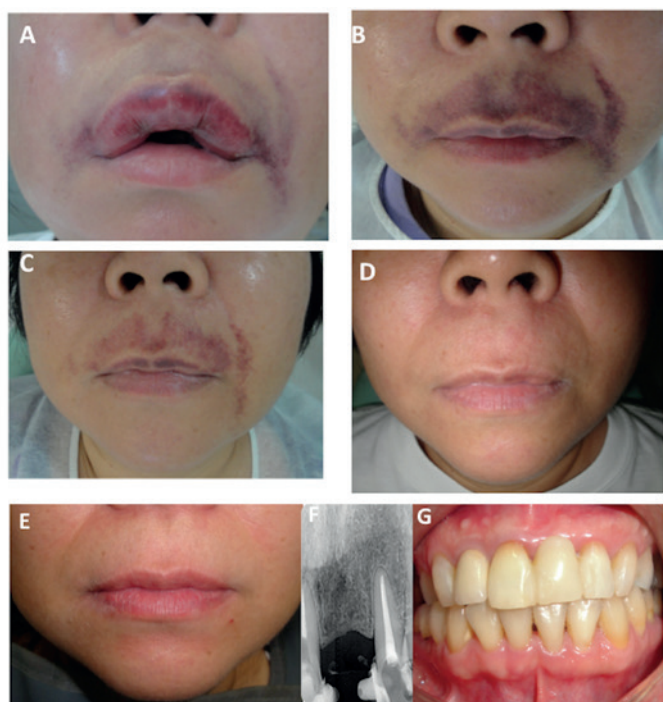Thirty days later, the patient was admitted again to continue her treatment. The working length was obtained again using an electronic method with the Root Zx II apex locator (J. Morita, Japan) and was diagnosed a root perforation at the apical third. This perforation may have contributed to the increase in extrusion of the NaOCl to the apical region.

After informed consent obtained from the patient, a certification of the case report was granted by the Institutional Ethics Committee (Pr.# 31447814.1.0000.0021).

### DISCUSSION

Root canal retreatments in teeth presenting secondary infection routinely have been indicated 2.5% sodium hypochlorite as irrigant solution aiding the sanitization process during instrumentation<sup>5,24</sup>. In the present case report, the imaging features showed a large root canal which in function of clinical management during root canal retreatment favored the extrusion of sodium hypochlorite beyond of root apexes.

Sodium hypochlorite is a strong base and the main chemical irrigating solution regularly used for root canal treatment<sup>2,3,5,24</sup>. This solution is available at different concentrations, and its an-



**Figure 2** - Appearance of the patient at 18 hours (A), 3 days (B), 6 days (C), 11 days (D), and 17 months (E-G) after the accident.

timicrobial capacity and tissue dissolution is more effective at higher concentrations, however, inversely proportional to its tissue tolerance<sup>2,5</sup>. Currently, due to rapid RCP using nickel-titanium rotatory instruments and reciprocating systems, sodium hypochlorite has been used at larger concentrations. In function of sodium hypochlorite remains inside the root canal, there will be no harmful postoperative consequences for the patient<sup>5</sup>. However, in cases of ample contact with the apical tissues, accidents and its complications have been identified<sup>10-23</sup>.

Inadvertent injection of sodium hypochlorite beyond the apical foramen can occur due to an incorrect determination of the endodontic working length, iatrogenic widening of the apical foramen, lateral perforation, or wedging of the irrigating needle. If a wide opening between the root canal and the periodontal tissues exists, the dentist must perform specific care to prevent a NaOCl accident or consider the use of an alternative irrigation solution.<sup>16</sup> If NaOCl comes into contact with periodontal tissues, then tissue necrosis can occur due to its excellent tissue dissolution capacity<sup>21</sup>.

Several reports<sup>10-25</sup> have demonstrated severe complications in the surrounding areas of the sodium hypochlorite extrusion spot. Such complications, including emphysema, which is caused by oxygen liberation into the tissues, severe pain, ecchymosis, hematoma and swelling have been frequently described<sup>16,18,20</sup>. The toxic effect in the adjacent areas is caused by an alkaline solution, which can penetrate further into the adjacent tissues, thereby causing larger zones of coagulation<sup>25</sup>. Some severe complications from origin of NaOCl infusion beyond the root apex may be described as chemical burns and tissue necrosis, neurological complications (paraesthesia, anaesthesia affecting the mental, inferior dental and infraorbital branches of the trigeminal nerve), and upper airway obstruction<sup>23</sup>.

The patient clinical history reported that experienced an immediate burning sensation, which was accompanied by an acute,

persistent and severe pain. In addition soon after in the area of the maxillary incisor it was observed pronounced swelling in upper lip. The diagnosis hypothesis was sodium hypochlorite extrusion beyond apex root. The systemic treatment proposed was immediately a single oral dose of 8 mg of corticosteroids. Amoxicillin (1.5g/day in 3 times) over 6 consecutive days) and anti-inflammatory (Nimesulide 100 mg, twice daily dose over 6 consecutive days) were prescribed. The tooth was accessed again and copious irrigation with sterile saline was performed. To help the control of inflammation, low level laser therapy was implemented in the swelling areas for 3 and 18 hours after the accident, and 3, 6 and 11 days subsequently. The pain and swelling progressively decreased, and although there was extensive ecchymosis, no skin necrosis was found. After 4 days, the patient presented no pain and the swelling area had total remission on day 11. Thirty days later, the patient continued the treatment.

The use of potent anti-inflammatory drugs is highly recommended immediately after the accident<sup>26</sup>. Antibiotics should be administered if there is any clinical evidence of wound infection or if necrosis is imminent<sup>15</sup>. With regard to the present accident, an antibiotic was prescribed because it should be used prophylactically in any case of sodium hypochlorite extrusion. When the extrusion occurs, there is no way to know if necrosis and infections can develop.

In addition to existing treatment protocols,<sup>27-31</sup> this report suggests the use of low-level laser therapy (LLLT)<sup>28-32</sup> as adjuvant to better control of inflammatory process. LLLT has been used in postoperative surgeries because it can improve tissue response and reduce pain and swelling<sup>28-30</sup>. Thus, an LLLT protocol is an additional alternative for the treatment of swelling and pain after sodium hypochlorite accidents into periodontal tissues.

Some steps can be taken to avoid sodium hypochlorite extrusion accidents; for instance, good working length control, placement of the irrigation needle 1 mm to 3 mm short of working length, passive and not locked placement of needle in the root canal, slow expression of the irrigant into the root canal, use of negative pressure during irrigation and use of lower concentrations of sodium hypochlorite<sup>20,21,23</sup>. Moreover, it is important to recognize both the length and integrity of the root canal prior to the start of irrigation with any concentration of sodium hypochlorite<sup>20,23</sup>. There is no doubt that the sodium hypochlorite solution is important to infection control during root canal treatment, however, must be used with careful attention via the previously described steps. The severe tissue damage caused by sodium hypochlorite extrusion into periapical tissues must be prevented and avoided.

After recognition of the accident, antibiotics and anti-inflammatory drugs should be immediately prescribed. Although additional studies are necessary, an LLLT protocol can improve the time of recovery and result in more comfortable conditions for the patient.

#### ACKNOWLEDGEMENTS

The authors have no conflicts of interest in this case report.

#### REFERENCES

- Hasselgren G, Olsson, B, Cvek, M. Effects of calcium hydroxide and sodium hypochlorite on the dissolution of necrotic porcine muscle tissue. *J Endod.* 1988; 14(3): 125-7.

02. Zehnder M. Root canal irrigants. *J Endod.* 2006; 32(5): 389-98.
03. Hapassalo M, Shen Y, Qian W, Gao Y. Irrigation in endodontics. *Dent Clin North Am.* 2010; 54(2): 291-312.
04. Stojicic S, Zivkovic S, Qian W, Zhang H, Haapasalo M. Tissue dissolution by sodium hypochlorite: effect of concentration, temperature, agitation and surfactant. *J Endod.* 2010; 36(9): 1558-62.
05. Estrela C, Estrela CRA, Barbin EL, Spanó JC, Marchesani MA, Pécora JD. Mechanism of action of sodium hypochlorite. *Braz Dent J.* 2002; 13(2): 113-17.
06. Spångberg L, Engström B, Langeland K. Biologic effects of dental materials. 3. Toxicity and antimicrobial effect of endodontic antiseptics in vitro. *Oral Surg. Oral Med Oral Pathol.* 1973; 36(6): 856-71.
07. Pashley EL, Birdsong NL, Bowman K, Pashley, DH. Cytotoxic effects of NaOCl on vital tissue. *J. Endod* 1985; 11: 525-58.
08. Hülsmann M, Hahn W. Complications during root canal irrigation - literature review and case reports. *Int. Endod. J* 2000; 33:186-93.
09. Harrison JW, Svec TA, Baumgartner JC. Analysis of clinical toxicity of endodontic irrigants. *J. Endod* 1978; 4: 6-11.
10. Ehrlich DG, Brian JD Jr, Walker WA. Sodium hypochlorite accident: inadvertent injection into maxillary sinus. *J. Endod* 1993; 19:180-82.
11. Reeh ES, Messer HH (1989). Long-term paraesthesia following inadvertent forcing of sodium hypochlorite through perforation in maxillary incisor. *Endod. Dent. Traumatol* 1989; 5:200-03.
12. Kaufman AY, Keila S. Hypersensitivity to sodium hypochlorite. *J. Endod* 1989; 15: 224-26.
13. Witton R, Brennan PA. Severe tissue damage and neurological deficit following extravasation of sodium hypochlorite solution during routine endodontic treatment. *Br. Dent. J* 2005; 198:749-50.
14. Gursoy UK, Bostanci V, Kosger HH. Palatal mucosa necrosis because of accidental sodium hypochlorite injection instead of anesthetic solution. *Int. Endod. J* 2006; 39:157-61.
15. Bowden JR, Brennan PA. Life-threatening airway obstruction secondary to hypochlorite extrusion during root canal treatment. *Oral Surg. Oral Med. Oral Pathol. Oral Radiol. Endod* 2006; 101:402-4.
16. Mehdipour O, Kleier DJ, Averbach RE. Anatomy of sodium hypochlorite accidents. *Compend Contin Educ Dent.* 2007;28(10):544-6,548,550.
17. Pelka M, Petschelt A. Permanent mimic musculature and nerve damage caused by sodium hypochlorite: a case report. *Oral Surg Oral Med Oral Pathol Oral Radiol Endod* 2008;106(3):e80-3.
18. Zairi A, Lambrianidis T. Accidental extrusion of sodium hypochlorite into the maxillary sinus. *Quintessence Int.* 2008;39(9):745-8.
19. Kleier DJ, Averbach RE, Mehdipour O. The sodium hypochlorite accident: experience of diplomats of the American Board of Endodontics. *J. Endod* 2008; 34:1346-50.
20. Zhu WC, Gyamfi J, Niu LN, Schoeffel GJ, Liu SY, Santarcangelo F, Khan S, Tay, K.C, Pashley DH, Tay FR. Anatomy of sodium hypochlorite accidents involving facial ecchymosis - A review. *J. Dent* 2013; 4: 935-48.
21. Kishor N. Oral tissue complications during endodontic irrigation. Literature review. *NY State Dental J* 2013; 79: 37-42.
22. Farreras DCR, Puente CG, Estrela C. Sodium hypochlorite chemical burn in an endodontist's eye during canal treatment using operating microscope. *J. Endod* 2014; 40: 1275-79.
23. Spencer HR, Ike V, Brennan PA. Review: the use of sodium hypochlorite in endodontics - potential complications and their management. *Br. Dent. J* 2007; 202:555-59.
24. Varise TG, Estrela C, Guedes DFC, Sousa-Neto MD, Pécora JD (2014). Detection of organochlorine compounds formed during the contact of sodium hypochlorite with dentin and dental pulp. *Braz. Dent. J* 2014; 25: 109-16.
25. Mitchell RP, Baumgartner JC, Sedgley CM. Apical extrusion of sodium hypochlorite using different root canal irrigation systems. *J Endod.* 2011;37(12):1677-81.
26. Motta MV, Chaves-Mendonça MA, Stirton CG, Cardozo HF. Accidental injection with sodium hypochlorite: report of a case. *Int Endod J.* 2009; 42(2): 175-82.
27. Hales JJ, Jackson CR, Everett AP, Moore SH. Treatment protocol for the management of a sodium hypochlorite accident during endodontic therapy. *Gen Dent.* 2001; 49(3): 278-81.
28. Gasperini G, Rodrigues de Siqueira IC, Rezende Costa L. Does low-level laser therapy decrease swelling and pain resulting from orthognathic surgery? *Int J Oral Maxillofac Surg.* 2014; 43(7): 868-73.
29. Gokçen-Rohlig B, Kipird S, Baca E, Kesin H, Sato S. Evaluation of orofacial function in temporomandibular disorder patients after low-level laser therapy. *Acta Odontol Scand.* 2013; 71(5): 1112-7.
30. Paschoal MA, Santos-Pinto L. Therapeutic effects of low-level laser therapy after premolar extraction in adolescents: a randomized double-blind clinical trial. *Photomed Laser Surg.* 2012; 30(9): 559-64.
31. Tunér J. Dental Laser Phototherapy. *Photomed. and Laser Sur.* 2014; 32(6): 313-4.
32. Pinheiro ALB, Nascimento SC, Vieira, LBA, Brugnara-Jr A, Zanin, F, Rolim AB, Silva PS. Effects of low-level laser therapy on malignant cells: in vitro study. *Photomed. Laser Surg.* 2007; 20(1): 23-6.

## RESUMO

**Objetivo:** Discutir uma extrusão acidental de hipoclorito de sódio 2,5% (NaOCl) tendo como recurso terapêutico adicional aplicação de laser de baixa intensidade. **Relato de caso:** paciente do sexo feminino, 39 anos, foi encaminhada para clínica de graduação e durante o preparo do canal relatou sensação de queimação a qual foi acompanhada de dor aguda e severa. Após três horas, a paciente retornou com dor espontânea, persistente e severa na área de incisivo superior e edema pronunciado em seu lábio superior. A hipótese diagnóstica foi acidente com extrusão de hipoclorito de sódio além do ápice radicular. A paciente recebeu imediatamente uma dose única de 8mg de corticosteroides e também foi prescrito

amoxicilina e anti-inflamatório. Para ajudar no controle da inflamação, terapia com laser de baixa intensidade (LLLT) foi realizada. **Resultados:** a paciente retornou 18 horas após e dor e edema decresceram gradualmente. Embora houvesse extensa equimose, nenhuma necrose tecidual foi observada. Após 4 dias, a paciente apresentou ausência de dor e o edema teve redução total no dia 11. No controle, 17 meses após, foi mostrado aspecto clínico com aparência normal. **Conclusões:** A terapia com antibióticos, anti-inflamatórios e LLLT para danos teciduais severos causados pelo NaOCl reduziram as manifestações de dor e edema.

**PALAVRAS-CHAVE:** Endodontia, Irrigantes do canal radicular, Hipoclorito de sódio, Prevenção de acidentes.

**AUTOR PARA CORRESPONDÊNCIA**

Professor Key Fabiano Souza Pereira,  
School of Dentistry, Federal University of  
Mato Grosso do Sul, MS, Brazil  
Senador Filinto Muller Avenue, Cidade Universitária, s/n  
Campo Grande, MS, Brazil; Zip Code: 79070-900;  
Tel: +55-67-3345-7383/ Fax: +55-67-3345-7385  
E-mail: keyendo@hotmail.com