

Dental enamel defects: teenagers' self perception versus dentists' perception

Alterações de esmalte dentário: percepções dos adolescentes versus dentistas

Naiara P. FERREIRA-NÓBILO¹; Nádia DESCHAMPS²; Sílvia CYPRIANO³; Maria L. R. SOUSA⁴

1. PhD Department of Public Health Dentistry, Piracicaba Dental School, University of Campinas, Brazil;

2. PhD. Department of Public Health Dentistry, Piracicaba Dental School, University of Campinas, Brazil;

3. PhD. Department of Public Health Dentistry, Piracicaba Dental School, University of Campinas, Brazil;

4. PhD. Department of Public Health Dentistry, Piracicaba Dental School, University of Campinas, Brazil.

ABSTRACT

Introduction: It is still not clear if enamel defects have any esthetic implication, especially when anterior teeth are affected. **Purpose:** The aim of this study was to evaluate how fluorosis has been perceived by teenagers and dental health professionals of different specialties and what kind of treatment those professionals are proposing. **Methods:** The sample consisted of 69 teenagers aged from 10 to 14-years that answered the following questions: "Are you satisfied with the appearance of your teeth?"; "Do you perceive any different aspects on your teeth?" "If so, what do you perceive?". The fluorosis diagnostic of upper front teeth was carried out by two epidemiologists through the analysis of the photographs of volunteers' teeth. The results from the epidemiologist were selected and showed the least intra-examiner error. The following ques-

tions about diagnostic and treatment attached to the photographs were answered by dentists from government services and specialists of Restorative dentistry and Pediatric dentistry: "Are there any visible alterations in the enamel of one or more teeth in the photograph?"; "What should your procedure be for the diagnostic found?". Hypothesis testing was carried out using chi-squared test for proportions at a significance level at $P=0.05$. **Results:** Fluorosis was perceived by 13.1% of the teenagers. The percentage of fluorosis diagnosed by the specialists and dentists from government services was 25.4% and 27.7%, respectively ($P>0.05$). **Conclusions:** The dental health professionals perceive more fluorosis than adolescents, and indicate invasive treatment for this condition.

KEYWORDS: Dental fluorosis; Enamel defects; Esthetic perception; Teenagers.

INTRODUCTION

Dental enamel alterations have widely been described in literature. These defects may result from disturbances in dental hard tissue matrix and its mineralization during the period of odontogenesis^{1,2}. One of the defects attributed to ingestion of fluoride during dental development is fluorosis. The prevalence of fluorosis has increased all over the world^{3,4}; and, in Brazil, fluorosis prevalence among 12-year-old children is at 16,7%⁵. However, enamel defects have also been described as diffuse opacities by some authors such as Almeida *et al.*⁶, who found the defect in 40% of permanent teeth in Portugal, and Elwood, Cortea and O'Mullane⁷ who found the defect in 17.9% in the north of Wales. Other kinds of enamel defects are enamel hypoplasia and demarcated opacity. In regard to hypoplasia, the prevalence ranges from 0.8% in Portugal¹ to 8.8% in the north of Wales⁷. The prevalence of demarcated opacities ranges from 7.1% to 34.6% in the same studies. However, it is not clear if those defects have any esthetic implication, especially when anterior teeth are affected.

The literature has shown several results on developmental defects of enamel perception by the population. In a study in Scotland⁸ with the participation of children with age average at 13.5-years, approximately half the sample had some sort of developmental defect of enamel. However, only 14% of the sample expressed concern about the presence of the defects.

The impact of fluorosis in school children was studied in Piracica-

ba-São Paulo⁹. The defect was found in 72% of the children through the diagnostic by the dental health professional, however this figure did not shatter the subjects' self-images. However, in another study¹⁰ individuals were subjected to a questionnaire in order to compare fluorosis esthetic perception and other tooth disturbances perceptions and concluded that even a mild fluorosis was perceived.

Although dentists can detect discrete levels of fluorosis¹¹, fluorosis does not necessarily mean dissatisfaction with the appearance of the teeth, for either the professional¹² or the layperson.

Thus, the decision for esthetic treatment must be discussed, given the fact that not only the professional's diagnostic but also the patient's perception and his will for the esthetic treatment must be taken into account.

The aim of this study was to evaluate how fluorosis has been perceived by teenagers, dentists of government services and specialists (Restorative dentistry and Pediatric dentistry) and what kind of treatment those professionals are proposing.

METHODS

This study was carried out in 2005, after being approved by the Ethic Committee of the School of Dentistry of Piracicaba.

The sample consisted of 69 teenagers (selected according to the suitability – intentional sample), who were drawn from a previous study, aged from 10 to 14-years, from government schools from cities

where the drinking water showed different levels of fluoride (Cordeirópolis, Assistência and Piracicaba). In the previous study, the children were selected to obtain different levels of fluorosis, using Dean's Index suggested by the World Health Organization¹³, that is, most affected teeth were selected and then, the least affected tooth of each group when teeth presented different levels of fluorosis, classified as: (0) "normal", (1) "questionable", (2) "very mild", (3) "mild", (4) "moderate", (5) "severe". Thus, a sample with individuals with different levels of fluorosis was obtained, not disconsidering also teeth with normal enamel (code 0), to obtain the classification "presence/absence" of fluorosis. In the present study the teenagers were evaluated by photographs considering only upper front teeth (canines, central and lateral incisors) and not all teeth as in that study. The pictures were taken by a single photographer using similar lighting, exposures and macro lens magnification ratio of 1:1.2, with the following photographic equipment: Nikon F-70 camera body, Medial Nikon 120mm lens and Nikon AC adapter AC UNIT LA-2 for Medical Nikon 120mm F4.

Two epidemiologists experienced in diagnosing dental fluorosis, eleven dentists from government services and eleven specialists of Restorative dentistry and Pediatric dentistry areas took part in this research. The fluorosis diagnostic of upper front teeth was carried out by the two epidemiologists through the analysis of the photographs of volunteers' teeth. The results from the epidemiologist were selected and showed the least intra-examiner error. The classification obtained (presence/absence of fluorosis) was compared to the teenagers' perception and the diagnostic of the professionals of different areas. For the purpose of data analysis, code 0 was classified as "absence of fluorosis" and the remaining were classified as "presence of fluorosis".

Teenagers' esthetic perception was obtained by a questionnaire when the photographs were taken. The questions were about the teenager's satisfaction and impact: "Are you satisfied with the appearance of your teeth?"; "Do you perceive any different aspects on your teeth?". The answers for that questions could be "Yes" or "No". At final, they answered to the open question: "If so, what do you perceive?".

The photographs were reproduced by a scanner and sent to the two epidemiologists (for diagnosing) and to the twenty-two dentists. There were questions about diagnostic and treatment attached to the photographs sent to the dentists. As for the diagnostic, the following questions were asked: "Are there any visible alterations in the enamel of one or more teeth in the photograph?" The multiple answers could be: "no enamel defects"; "enamel with white lesion"; "enamel with demarcated opacity"; "enamel with diffuse opacity, suggesting fluorosis"; "enamel with hypoplasia"; "I do not know". The answers obtained were divided into 5 categories for the results: "healthy enamel"; "white spots"; "fluorosis"; "opacity/hypoplasia"; "I do not know". Regarding the treatment, the dentists were asked the following question: "What should your procedure be for the diagnostic found?". The answers could be: 1. "no treatment"; 2. "no invasive treatment such as plaque or diet control, prophylaxis, fluoride therapy and dental bleaching"; 3. "esthetic restoration"; 4. "invasive treatment, such as restoration with esthetic or functional aims, microabrasion or prosthesis"; "I do not know". The answers 4 and 5 were considered invasive treatment, and the answers 2 and 3 not invasive treatment.

The statistical analysis was descriptive. Hypothesis testing was

carried out using chi-squared test for proportions at a significance level at $P=0.05$.

RESULTS

For specialists and dentists from government services that carried out diagnostic through photographs fluorosis was diagnosed in 25.4% and 27.7% of the sample, respectively ($p=0.3523$). When the diagnostic was carried by the epidemiologist, also through photographs, the result was 42%.

When the diagnostic of specialists and dentists from government services was compared with the pattern diagnostic (epidemiologic), the agreement was less than 80% for two specialists and for seven dentists from government services.

In the sample studied, the most teenagers (56.4%) do not have complaints and only 13.1% perceived spots in their teeth (fluorosis). The reasons for the discontent of teenagers are identified in Figure 1.

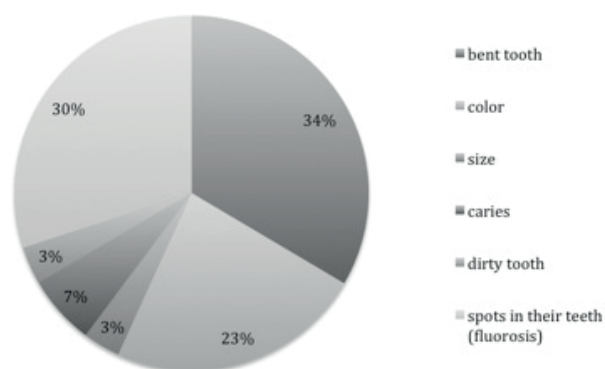


Figure 1 - Razons for the discontent of teenagers.

Seven teenagers (24.1%) of the 29 (42%) that had fluorosis diagnosed by the epidemiologists perceived the spots. Six of them were classified as belonging to the most serious levels of fluorosis and the other was classified as level 2. When the spots were not perceived, the individuals showed one of the first three levels of fluorosis.

When the treatment for the whole sample was proposed by the two professional categories, the specialists indicated invasive treatments for 20.28% of the cases, and the dentists of government services indicated those treatments for 17.52%. This difference was not significant ($P>0.05$).

When those professionals proposed treatment for fluorosis cases, the percentage of invasive treatments was higher: 38.81% (specialists) and 40.35% (dentists of government services). However the difference was not significant either.

DISCUSSION

The importance that fluorosis may represent in Collective Health, considering both the patient's perception and satisfaction with the appearance^{10,14,15,16} and the diagnostic and treatment carried out by the professionals^{17,18}, has been discussed in literature.

Although the percentage of fluorosis diagnosed by the specialists and dentists of government services (25.4% and 27.7%, respectively) was lower than that diagnosed by the epidemiologist (42%), it is still far higher than the fluorosis perceived by the teenagers (13.1%). This fact can influence the teenagers and their family members on esthetic concerns that the individuals have not developed yet.

Besides fluorosis, other aspects seem to disturb teenager's satis-

faction, such as position and color alterations, as evidenced by Menezes⁹ in a study involving Brazilian school children. In assessing the esthetic concerns from teenagers' parents, another study¹⁹ showed that concerns with alignment, spacing and crowding appeared to contribute more to the teenagers' parents dissatisfaction than did concerns with tooth color or blotchy appearance.

In our study, only one of the individuals that perceived spots showed level two of fluorosis (Dean Index), in the other cases fluorosis was perceived when it was at level 4 (four subjects) or 5 (two subjects). Fluorosis was not perceived by the other subjects of the study when it was at lower levels. This result is in agreement with Holloway and Ellwood²⁰, who found that small opaque spots are not regarded as a concern.

When the epidemiologist evaluated dental fluorosis through tooth diagnostic in the previous study, 68% of the sample was committed, being 56.51% of the levels classified as questionable, very mild and mild. The present study was carried out using part of the data of the previous research. Most of the cases of fluorosis diagnosed by specialists and dentists of government services in our study are levels 1 to 3, when the teenager does not perceive the defect.

Probably, a higher indication of invasive treatment in the group with presence of fluorosis than in the sample as a whole was the result of the sample selected (intentional) so all levels of fluorosis could be selected. However, it is important to emphasize that only teenagers with higher levels of fluorosis perceived its presence, through defects.

Thus, considering the results described for this sample, the decision for treatment should be taken into account professionals' and patient's opinions, avoiding the esthetic treatment of enamel alterations when it is not of concern to the patient.

CONCLUSIONS

The dental health professionals perceive more fluorosis than adolescents, and indicate invasive treatment for this condition.

REFERENCES

- Bhaskar SN. *Histologia e embriologia oral de Orban*. 10 th ed. Artes Médicas; 1989.
- Mohamed AR, Thomson WM, Mackay TD. An epidemiological comparison of Dean's index and the Developmental Defects of Enamel (DDE) index. *J Public Health Dent*. 2010; 70(4): 344-7.
- Beltrán-Aguilar ED, Barker L, Dye BA. Prevalence and severity of dental fluorosis in the United States, 1999-2004. *NCHS Data Brief*. 2010; (53): 1-8.
- Carvalho RWF, Valois RBC, Santos CNA, Marcellini PS, Bonjardim LR, Oliveira CCC et al. Estudo da prevalência de fluorose dentária em Aracaju. *Cienc Saude Coletiva*. 2010; 15(Supl 1): 1875-80.
- Brasil. Ministério da Saúde. Secretaria de Atenção à Saúde. Coordenação Nacional de Saúde Bucal. Projeto SB Brasil 2010. Pesquisa Nacional de Saúde Bucal 2010: resultados principais. Brasília; 2011.
- Almeida CM, Peterson PE, Andre SZ, Toscano A. Changing oral health status on 6 and 12-year-old school children in Portugal. *Community Dental Health*. 2003; 20(4): 211-216.
- Ellwood RP, Cortea DF, O'Mullane DM. A photographic study of developmental defects of enamel in Brazilian school children. *Int Dent J*. 1996; 46(2): 69-75.
- Fyffe HA, Deery C, Pitts NB. Developmental defects of enamel in regularly attending adolescent dental patients in Scotland; prevalence and patient awareness. *Community Dent Health*. 1996; 13(2): 76-80.
- Menezes LMB, Sousa MLR, Rodrigues LKA, Cury, JA. Autopercepção da fluorose pela exposição a flúor pela água e dentifrício. *Rev Saúde Pública*. 2002; 36(6): 752-4.
- McKnight CB, Levy, SM, Cooper SC, Jakobsen JR. A pilot study of esthetic perceptions of dental fluorosis vs. selected other dental conditions. *ASDC J Dent Child*. 1998; 65(4): 233-238.
- Ellwood R, O'Mullane D, Clarkson J, Driscoll W. A comparison of information recorded using the Thylstrup Fejerskov index, tooth surface index of fluorosis and developmental defects of enamel index. *Int dent J*. 1994; 44(6): 628-36.
- Lund AE. Have you ever diagnosed fluorosis in one of your pediatric patients, and do you regard fluorosis as a health issue? *JADA*. 1999; 130(8): 1163.
- World Health Organization. *Oral Health Surveys: Basics Methods*. 4th ed. Geneva: WHO; 1997.
- Michel-Crosato E, Biazevic MGH, Crosato E. Relationship between dental fluorosis and quality of life: a population based study. *Braz Oral Res*. 2005; 19(2): 150-5.
- Moysés, SJ, Moysés, ST, Allegretti ACV, Argenta M, Werneck R. Fluorose dental: ficção epidemiológica? *Rev Panam Salud Publica*. 2002; 12(5): 339-46.
- Sujak SL, Kadir RA, Dom TNM. Esthetic perception and psychosocial impact of developmental enamel defects among Malaysian adolescents. *J Oral Sc*. 2004; 46(4): 221-26.
- Riordan PJ. Specialists clinicians' perceptions of dental fluorosis. *ASDC J Dent Child*. 1993; 60(4-5): 315-20.
- Shulman JD, Maupomé G, Clark DC, Levy SM. Perceptions of desirable tooth color among parentes, dentists and children. *JADA*. 2004; 135(5): 595-604.
- Levy SM, Warren JJ, Jakobsen JR, Broffitt S, Nielsen B. Factors associated with parents' esthetic perceptions of children's mixed dentition fluorosis and demarcated opacities. *Pediatr Dent*. 2005; 27(6): 486-492.
- Holloway PJ, Elwood RP. The prevalence, causes and cosmetic importance of dental fluorosis in the United Kingdom: a review. *Community Dent Health*. 1997; 14(3): 148-55.

RESUMO

Introdução: Ainda não está bem esclarecido se as alterações de esmalte dental têm algum significado estético, em especial quando afetam dentes anteriores. **Objetivo:** O objetivo deste estudo foi avaliar como a fluorose dental está sendo percebida por adolescentes e profissionais de diferentes especialidades e que tipo de tratamento esses profissionais estão propondo. **Métodos:** A amostra consistiu de 69 adolescentes de 10 a 14 anos, que

responderam às seguintes perguntas: "Você está satisfeito com a aparência de seus dentes?", "Você percebe algo diferente em seus dentes?", "Se sim, o que você percebe? Foi realizado o diagnóstico de fluorose dos dentes anteriores por 2 epidemiologistas. Foram selecionados os resultados do epidemiologista com menor erro intraexaminador. Paralelamente, profissionais especialistas e de saúde bucal coletiva, responderam às seguintes questões com relação às mesmas fotos: "Existe alguma alteração

visível no esmalte de um ou mais dentes desta foto?"; "Qual a sua conduta para a condição diagnosticada?". Utilizou-se o Teste do Qui Quadrado com significância de 5%. Resultados: Dos adolescentes, 13,1% perceberam a presença de fluorose, sendo que outros fatores parecem incomodá-los mais, como problemas de posição e cor. Os especialistas e os profissionais da rede

pública diagnosticaram igualmente fluorose em 25,4% e 27,7% ($p>0,05$). Conclusões: Os profissionais de saúde bucal percebem mais fluorose do que os adolescentes, e indicam tratamento invasivo para esta condição.

PALAVRAS-CHAVE: Fluorose dental; Defeitos do esmalte; Percepção; Adolescentes.

AUTOR PARA CORRESPONDÊNCIA

Profa. Dra. Maria da Luz Rosário de Sousa
Avenida Limeira, 901 – Areião. Piracicaba-SP. CEP 13414-018
Tel +55 19 2106 5364
E-mail: luzsousa@fop.unicamp.br