

# Analysis of the mandibular foramen position and its implications to the inferior alveolar nerve block

Análise da posição do forame mandibular e suas implicações para o bloqueio do nervo alveolar inferior

Renato R. S. BRAGA<sup>1</sup>, Lilian M. T. SILVA<sup>2</sup>, Paulo A. GALVANINI<sup>3</sup>, Petrus P. GOMES<sup>4</sup>, Fausto R. VICTORINO<sup>5</sup>

1 - Department of Dentistry, University Center of Maringá-UNICESUMAR, Maringá, PR, Brazil.

2 - Center of Tomography and Diagnosis, Maringá, PR, Brazil.

3 - Department of Dentistry, University Center of Maringá-UNICESUMAR, Maringá, PR, Brazil.

4 - Department of Dentistry, University Center of Maringá-UNICESUMAR, Maringá, PR, Brazil.

5 - Department of Dentistry, University Center of Maringá-UNICESUMAR, Maringá, PR, Brazil.

## ABSTRACT

The aim of this study was analyze the positioning of the mandibular foramen in men and women, relating it to the inferior alveolar nerve block. Were analyzed CBCT scans of the mandible of 25 women and 25 men, aged between 20 and 40 years, with toothed jaws, presence of the second molar erupted and in occlusion. To determine the position of the mandibular foramen, three measurements were taken in millimeters, Point A - distance from the foramen to the anterior border of the mandible; Point B - distance between the foramen to the base of the mandible and Point

C - distance between the foramen and the mandibular notch. The mean measure point A was 11.8 mm and when compared the points A, B and C between the right and left sides, there was no significant difference, however men and women have significant differences were detected for point B and point C. Conclude that in men and women, can use needles with at least 21mm in length with the insertion in the level of occlusal plane for blocking the inferior alveolar nerve, enhancing the success of this procedure.

**KEYWORDS:** Mandible; Cone-Bean computed tomography; Nerve block; Mandibular nerve.

## INTRODUCTION

The knowledge of the topography of the nervous structures of the head and neck, especially the branches of the trigeminal nerve is of extreme importance to the execution of local anesthetic techniques in dentistry.

The foramen through which penetrates the inferior alveolar nerve is located on the medial aspect of the mandibular ramus, a few millimeters above the occlusal plane of the molars, and approximately at the midpoint of the mandibular ramus, closer to the coronoid notch. However, the location of the foramen is not the same in all subjects, presenting some anatomical variations<sup>1</sup>. To obtain the inferior alveolar nerve block is necessary a rapid distribution of local anesthetic solution from the infratemporal fossa to the mandibular foramen, and the needle positioned far from the mandibular foramen, prevents the local anesthetic to reach the inferior alveolar nerve. Some authors report that difficulty in obtaining anesthesia of the inferior alveolar nerve usually is reason of failing to observe the position of the foramen<sup>2,3</sup>. Textbooks of local anesthesia in dentistry have suggested the use of long needle for the execution of anesthetic technique for the inferior alveolar nerve block<sup>3</sup>. However, the Nery de Lima & Céspedes<sup>1</sup> in their study analysing dry mandibles, observed the possibility of use of short needles (25mm) for the inferior alveolar nerve block due to the position of the mandibular foramen.

Thus, the objective of this study was to analyze the position of the mandibular foramen in men and women by Cone-Bean Computed Tomography (CBCT) and to relate the information

to the anesthesia technique of the inferior alveolar nerve block.

## METHODOLOGY

We analyzed 50 CBCT scans of the mandible, including 25 women and 25 men ranging from 20 to 40 years, presenting non-edentulous jaws with the presence of the second molar erupted and in occlusion, from a database of a Dental Radiography Center. Thus, patients were not unnecessarily exposed to radiation and their identities remained confidential. CBCT imaging of patients who had missing teeth or a pathologic lesion causing asymmetry and deviation of the mandible were excluded from the study.

To obtain CBCT images a CBCT scanner model classic i-CAT (Imaging Science Int'l, Hatfield, Pa, USA) was used, which carried out the procedure with 120kV, 8mA and an exposure time of 20s, a voxel size of 0.3mm and the panoramic thickness was 20.1mm.

After proper positioning, the device was activated so that the detector tube system perform a 360° turn around the patient's head, scanning the structures in slices of 0.25 mm module with a high resolution and accuracy, without magnification or distortion. The 3D volumetric images of the maxilla and mandible were reformatted and displayed using the iCAT software developed by the manufacturer of the equipment. With the same processing software measurements of the images were taken to the study.

Initially, for determining the position of the mandibular foramen

men two lines were drawn, one horizontal, parallel to the occlusal surface of the lower teeth and another vertical passing through the foramen of both jaws. From these lines, the following measures were taken in millimeters: Point A - distance between the lateral border of the mandibular foramen to the external cortex of the anterior border of the mandible branch; Point B - distance between the bottom edge of the mandibular foramen to the outer cortical base jaw and Point C - distance between the upper edge of the mandibular foramen until the lowest point of the notch of the jaw, as shown in Figure 1.

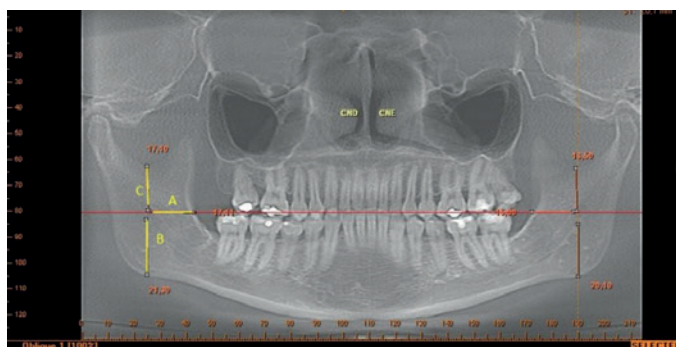


Figure 1 - CBCT scan panoramic view, showing points A, B and C.

Statistical analysis was performed using the software GraphPad Prism 5.00 (GraphPad Software, San Diego, Ca, USA). Descriptive statistics were determined for each variable. Comparisons were made for each variable left and right sides, using the Student t test. The level of statistical significance for the study was 5%.

## RESULTS

The mean and standard deviation of the points A, B and C are shown in Table 1. By comparing the points A, B and C between the right and left sides, no significant differences were detected, as shown in Table 2.

Among men and women only significant difference was detected for Point B and Point C, as shown in Table 3.

## DISCUSSION

To obtain the inferior alveolar nerve block is necessary a rapid distribution of the anesthetic solution from infratemporal fossa to the mandibular foramen, so the needle should be positioned next to it, allowing the anesthetic to reach the inferior alveolar nerve<sup>4</sup>.

The success rate of the inferior alveolar nerve block is smaller than most of the maxillary nerve blocks due to factors such as the depth of needle penetration into the soft tissues, accessory innervation<sup>5</sup> and anatomical variation of the position of the mandibular foramen<sup>4</sup>, therefore the correct positioning of the needle is crucial, thus avoiding the anesthetic to be deposited far below or beyond the target area. The deposition of the anesthetic solution into the posterior region of the mandibular ramus can reach part of the parotid gland and the facial nerve, causing paralysis and great discomfort to the patient.

The clinical importance in knowing the position of the mandibular foramen, has been emphasized since 1984 by Bennet<sup>6</sup>, which advocated a bi-digital measurement of the thickness of

Table 1 - Mean values in millimeters and standard deviation at Points A, B e C.

	Point		
	A	B	C
n	50	50	50
Mean	11.81	21.45	15,03
Standard deviation	2.54	3.90	2.97

Table 2 - Mean in millimeters, standard deviation, lower values, maximum and P values of points on the right and left sides

Measurements	Side	Mean	SD	Minimum	Maximum	P value
A	R	11.36	2.376	7.50	17.11	0.081
	L	12.26	2.728	6.10	19.20	
B	R	21.68	4.103	15.00	34.21	0.562
	L	21.22	3.716	14.40	32.10	
C	R	14.76	2.756	9.60	23.41	0.367
	L	15.30	3.193	9.30	22.50	

No statistical difference was observed between the groups ( $p > 0,05$ ).  
SD: standard deviation

Table 3 - Mean values in millimeters and standard deviation at Points A, B e C according to gender.

	n	Point A		Point B		Point C	
		Mean	SD	Mean	SD	Mean	SD
Women	50	11.58	2.489	20.11	2.551	13.94	2.453
Men	50	12.04	2.683	22.79*	4.537	16.12*	3.080
P Value		0.374		0.004		0,0002	

\*Statistical difference ( $p < 0,05$ ).

SD: standard deviation

the mandibular ramus, because they considered that the foramen would be positioned in the middle of it in a anteroposterior direction. However, in 2006, Strini et al.<sup>7</sup>, analyzing dry mandibles, found that the mandibular foramen presents itself in the intermediate third of the mandibular ramus in height and posterior in a anteroposterior direction.

In the present study, the mandible was not divided in thirds, instead a measurement in the anteroposterior direction was taken, with reference to its anterior border (point A), which is the anatomical structure used as a reference for needle insertion during the inferior alveolar nerve block<sup>8</sup>. The results showed an overall average, in men and women, of 11.81 mm to Point A. It

was also observed that there was no significant difference when compared between genders and between the right and left sides. This average value, together with the approximately 7 mm soft tissue<sup>1</sup>, may give a value of 18.8 mm for the distance between the puncture site and the mandibular foramen. As needles may present lengths ranging from 21 to 25mm depending on the manufacturer, you could successfully use them to perform this technique with a lower risk for the parotid gland and reducing patient discomfort as well. Similar results were found by Nery de Lima & Céspedes<sup>1</sup>, in their study using dry skulls.

Some authors found higher values for the point A, as is the case in Lima et al.<sup>9</sup>, which measured the distance between the anterior border of the ramus to the lingula, finding a mean value of 19.48 mm. Smaller values were described by Prado et al.<sup>10</sup>, who found average distances of approximately 18 mm between the center of the mandibular foramen and the anterior border of the ramus in dentated jaws and Chrcanovic et al.<sup>11</sup>, who found in their measurements, a distance of 17.5 mm between the anterior border of the ramus and the anterior wall of the mandibular foramen. This difference between the results of previous studies may be related to anatomical structures used by them as a reference for the measurements. In the present study we used the anterior border of the mandibular foramen and the anterior border of the mandibular ramus, on the same level of the occlusal plane line of the posterior mandibular teeth, because drawing this line, it was noted that the mandibular foramen was always on the same height. This line is the same used as a clinical reference, refuting the findings from Kang et al.<sup>12</sup>. Another feature of the present study was the use of CBCT scan examination of patients and not the use of photographic images of skulls, as in studies of Ennes e Medeiros<sup>8</sup> and Lima et al.<sup>9</sup> or directly on dry skulls as Mendoza et al.<sup>13</sup>, Strini et al.<sup>7</sup> and Nery de Lima e Céspedes<sup>1</sup>.

The presence of the mandibular foramen in the middle third of the ascending ramus, at the level of the occlusal line of the posterior teeth, was confirmed by the values found for the points B and C and also by a line parallel to the occlusal plane before initiating measures. This result is also consistent with literature reports<sup>7,8</sup>.

When comparing the points A, B and C between right and left sides, although there was little difference, no statistical difference was observed (Table 2), demonstrating symmetry between the sides. A similar result was also observed in the study by Valente et al.<sup>14</sup>, in skulls. Only points B and C exhibited significant differences between men and women. Kane et al.<sup>15</sup> and Lo et al.<sup>16</sup> also found significant differences between the position of the mandibular foramen in relation to gender. In adults it can be said that the differences observed in the skull, refer to the female muscle frailty. This condition determines a smaller development of the mandibular ramus, which affects the position of the mandibular foramen<sup>10</sup>.

## CONCLUSION

According to the results obtained and literature review on the subject, it is concluded that in men and women, despite of the difference in positioning of the foramen of the mandible, needles 21mm to 25mm long can be used with minimum trauma during its insertion, which should be accomplished at the level of the occlusal plane in the retromolar area for inferior alveolar

nerve block and thereby minimizing the risk of violating adjacent anatomical structures favoring the success of the technique.

**Conflict of interest:** The authors state no conflict of interest in connection with the submitted work.

## Aknowledgment

The authors thank the University Center of Maringá (CESUMAR) for granting the scholarship PROBIC to develop this study.

## REFERENCES

01. Nery de Lima A, Céspedes IC. Fatores que levam ao sucesso da anestesia Pterigomandibular. *Rev Odonto*. 2009; 17(33): 71-8.
02. Moura W, Callestini E, Saad M. Revisão das técnicas intrabucais para anestesia dos nervos alveolar inferior, lingual e bucal. *Rev Assoc Paul Cir Dent*. 1984; 5(1): 23-30.
03. PotoEnik I, Bajrović F. Failure of inferior alveolar nerve block in endodontics. *Endod Dent Traumatol*. 1999; 15(6): 247-251.
04. Takasugi Y, Furuya K, Moriya K, Okamoto Y. Clinical evaluation of inferior alveolar nerve block by injection into the pterygomandibular space anterior to the mandibular foramen. *Anesth Prog*. 2000; 47(4): 125-9.
05. PotoEnik I, Bajrović F. Failure of inferior alveolar nerve block in endodontics. *Endod Dent Traumatol*. 1999;15(6): 247-51.
06. Bennett CR. Anestesia local e controle da dor na prática dentária. 6. ed. Rio de Janeiro: Guanabara Koogan; 1984. p. 59-69.
07. Strini PJS, Silva Júnior W, Rodrigues DA, Strini PJS, Guimarães EC, Bernardino Júnior R. Avaliação topográfica do forame mandibular em peças anatômicas maceradas parcialmente dentadas e edêntulas. *RFO UPF*. 2006; 11(2): 11-5.
08. Ennes JP, Medeiros RM. Localization of Mandibular Foramen and Clinical Implications. *Int. J. Morphol*. 2009; 27(4): 1305-11.
09. Lima DSC et al. Estudo anatômico do forame mandibular e suas relações com pontos de referência do ramo da mandíbula. *Rev Bras Cir Craniomaxilofac*. 2011; 14(2): 91-6.
10. Prado FB, Groppo FC, Volpato MC, Caria PHF. Morphological changes in the position of the mandibular foramen in dentate and edentate Brazilian subjects. *Clinical Anatomy*. 2010; 23(4): 394-8.
11. Chrcanovic BR, Abreu MH, Custódio AL. Morphological variation in dentate and edentulous human mandibles. *Surg Radiol Anat*. 2011; 33(3): 203-13.
12. Kang SH, Byun IY, Kim JH, Park HK, Kim MK. Three-dimensional anatomic analysis of mandibular foramen with mandibular anatomic landmarks for inferior alveolar nerve block anesthesia. *Oral Surg Oral Med Oral Pathol Oral Radiol*. 2013; 114(6): e17-23.
13. Mendoza CC, Vasconcelos BCE, Sampaio G, Cauás M, Batista JEM. Localização topográfica do forame mandibular: estudo comparativo em mandíbulas humanas secas. *Rev Cir Traumatol Buco-Maxilo-Fac*. 2004; 4(2): 137-42.
14. Valente VB, Arita WM, Gonçalves PCG, Campos JADB, Capote TSO. Location of the Mandibular Foramen According to the Amount of Dental Alveoli. *Int. J. Morphol*. 2012; 30(1): 77-81.
15. Kane AA, Lo LJ, Chen YR, Hsu KH, Noordhoff MS. The course of the inferior alveolar nerve in the normal human mandibular ramus and in patients presenting for cosmetic reduction of the mandibular angles. *Plast Reconstr Surg*. 2000; 106(5): 1162-74.
16. Lo LJ, Wong FH, Chen YR. The position of the inferior alveolar nerve at the mandibular angle: an anatomic consideration for aesthetic mandibular angle reduction. *Ann Plast Surg*. 2004; 53(1): 50-5.

**RESUMO**

O objetivo do presente estudo foi analisar o posicionamento do forame da mandíbula em homens e mulheres, relacionando-o ao bloqueio do nervo alveolar inferior. Foram analisados exames tomográficos da mandíbula de 25 mulheres e 25 homens com idade entre 20 e 40 anos, com mandíbula dentada, presença do segundo molar inferior irrompido e em oclusão. Para a determinação do posicionamento do forame da mandíbula, foram realizadas três medidas em milímetros, sendo: Ponto A – distância do forame até a borda anterior do ramo da mandíbula; Ponto B – distância entre o forame até a base da mandíbula e Ponto C

– distância entre o forame e a incisura da mandíbula. A medida média do Ponto A foi de 11,8mm e ao comparar os Pontos A, B e C entre os antímeros direito e esquerdo, não foi observada diferença significativa, já entre homens e mulheres foi detectada diferença significativa para o ponto B e ponto C. Conclui-se que em homens e mulheres, pode-se utilizar agulhas com no mínimo 21mm de comprimento com inserção ao nível do plano oclusal para o bloqueio do nervo alveolar inferior, melhorando o êxito deste procedimento.

**PALAVRAS-CHAVE:** Mandíbula; Tomografia computadorizada Cone-Bean; Bloqueio nervoso; Nervo mandibular.

**AUTOR PARA CORRESPONDÊNCIA**

Dr. Fausto Rodrigo Victorino

Rua Formosa, 489, Centro, CEP: 86990-000 – Marialva,  
PR, Brasil

Telefone: +55 44 99644534

E-mail: frvictorino@ig.com.br