

The role of toll-like receptor 4 in the pathogenesis of periapical lesions in experimental models: a scoping review

Ricardo Barbosa LIMA¹; Andressa da SILVA²; Clara Marina Pereira Cavalcanti SILVA³; Paulo NELSON-FILHO⁴; Léa Assed Bezerra DA SILVA⁵; Raquel Assed Bezerra da SILVA⁶

1 - Cirurgião-dentista, Programa de Pós-Graduação em Odontopediatria, Departamento de Clínica Infantil, Faculdade de Odontologia de Ribeirão Preto - Universidade de São Paulo, Ribeirão Preto, SP, Brasil; **2** - Cirurgião-dentista, Faculdade de Odontologia de Ribeirão Preto - Universidade de São Paulo, Ribeirão Preto, SP, Brasil; **3** - Cirurgião-dentista, Mestra em Ciências - Odontopediatria, Programa de Pós-Graduação em Odontopediatria, Departamento de Clínica Infantil, Faculdade de Odontologia de Ribeirão Preto - Universidade de São Paulo, Ribeirão Preto, SP, Brasil; **4** - Docente, Doutor em Ciências Odontológicas - Odontopediatria, Departamento de Clínica Infantil, Faculdade de Odontologia de Ribeirão Preto - Universidade de São Paulo, Ribeirão Preto, SP, Brasil; **5** - Docente, Doutora em Ciências Odontológicas - Odontopediatria, Departamento de Clínica Infantil, Faculdade de Odontologia de Ribeirão Preto - Universidade de São Paulo, Ribeirão Preto, SP, Brasil; **6** - Docente, Doutora em Ciências - Odontopediatria, Departamento de Clínica Infantil, Faculdade de Odontologia de Ribeirão Preto - Universidade de São Paulo, Ribeirão Preto, SP, Brasil.

Abstract

Objective: To describe the state of the art on the role of the toll-like receptor 4 in the pathogenesis of periapical lesions in experimental models. **Methods:** A systematic search procedure was carried out to reach the available literature on the subject in databases and specialized scientific journals: MEDLINE, Embase, Web of Science, Google Scholar, International Endodontic Journal, Journal of Endodontics and Australian Endodontic Journal. **Results:** Four studies were included in the scope of the review. From an operational point of view, all studies induced the formation of periapical lesions by contamination of root canals. The experimental models were rats and mice, including animals that were wild-type or that had mutation or knockout in *Tlr4* gene. In general terms, TLR4 signaling was associated with inflammation and resorption of periapical tissue in wild-type mice and rats. The expression of this receptor tends to increase along the pathogenesis of periapical lesions. In TLR4-deficient mice, controversial outcomes have been observed. In a lipopolysaccharide hyporesponsive model due to *Tlr4* mutation, there is evidence of reduced periapical bone resorption. However, one study did not observe these differences. Current studies have significant limitations to consolidate these outcomes, including the number of animals in the experiments, statistical analyzes and experimental periods used. **Conclusion:** It is possible to conclude that TLR4 may act significantly in the genesis and development of periapical lesions in experimental models.

KEYWORDS: Endodontics; Periapical Diseases; Toll-Like Receptor 4.



Copyright © 2024 Revista Odontológica do Brasil Central - This work is licensed under a Creative Commons Attribution-NonCommercial-ShareAlike 4.0 International License(CC BY-NC-SA 4.0)

Received: 23/10/23
Accepted: 19/03/24
Published: 04/07/24

DOI: 10.36065/robrac.v33i92.1725

CORRESPONDING AUTHOR

Ricardo Barbosa Lima

Programa de Pós-Graduação em Odontopediatria, Departamento de Clínica Infantil, Faculdade de Odontologia de Ribeirão Preto - Universidade de São Paulo, Avenida do Café, s/n, Vila Monte Alegre, Ribeirão Preto, São Paulo, Brasil. CEP: 14.040-904
E-mail: ricardobarbosalima@usp.br

Introduction

Periapical lesions result from a long-lasting chronic inflammatory process caused by the presence of microorganisms and their products or by-products in the periapical region, considering the attempt of the host's immune system to fight the infection¹⁻⁴. There is a predominance of Gram-negative anaerobic bacteria during the development of these lesions, with lipopolysaccharides (LPS) in their outer cell membrane. When released during these bacterias' division, stress, or death, LPS molecules trigger different events that initiate and/or exacerbate the inflammatory response and bone reabsorption⁵⁻⁹.

From a host defense perspective, Toll-like receptors (TLRs) are pathogen recognition receptors (PRRs) that recognize pathogen-associated molecular patterns (PAMPs), such as LPS and other bacterial lipoproteins during infection processes^{10,11}, and induce the recruitment of immune cells to the site of aggression, initiating the inflammatory molecular cascade by releasing pro-inflammatory cytokines¹²⁻¹⁴. These events occur through the assembly of the MyD88 molecule and the interferon- β adapter inducer, two distinct signaling pathways that activate pro-inflammatory transcriptional responses through the NF- κ B pathway¹⁵⁻¹⁷.

When considering the state of the art regarding the role of TLRs in the pathogenesis of oral diseases, such as apical periodontitis, investigating the role of Toll-like receptor 2 (TLR2), it was demonstrated that *Tlr2* knockout (KO) mice had larger periapical lesions and an increased number of osteoclasts when compared to wild-type mice. The absence of TLR2 influenced the pathogenesis of periapical lesions, suggesting that this type of receptors is relevant to understanding the molecular dynamics during the genesis and development of these oral disease¹⁸. Furthermore, it has also been demonstrated that the MyD88 adapter molecule plays an important role in the development of experimentally induced apical periodontitis in mice, as its

absence (KO model) triggered larger periapical lesions and intense inflammatory infiltrate after activation of different TLRs¹⁹. In parallel, the absence of TLR2 and MyD88 can modulate the expression of matrix metalloproteinases (2 and 9), influencing the development of periapical lesions²⁰.

After these investigations and outcomes, another question arose: in addition to TLR2, do other TLRs, such as TLR4, play important roles in the pathogenesis of periapical lesions? Among the TLRs already described, the Toll-like receptor 4 (TLR4) stands out due to its involvement in the pathogenesis of several human diseases. During an infection, TLR4 responds to LPS by activating an intracellular signaling cascade that produces pro-inflammatory mediators, characterizing the host response^{21,22}. Therefore, the interaction of this receptor with immune-mediated systemic pathological processes has been investigated and reported^{14,23-26}. However, as far as we know, there is no synthesis of the state of the art about the role of TLR4 in the pathogenesis of periapical lesions in experimental models. Hereupon, the objective of this study was to describe the state of the art on the role of the toll-like receptor 4 in the pathogenesis of periapical lesions in experimental models.

Methods

Design

This was a bibliographic study, as a scoping review, following systematic procedures to recover, evaluate and synthesize the state of the art, following the guidelines described by Peters *et al.*²⁷ (2015) and Lockwood *et al.*²⁸ (2019). As steps for this objective, a guiding question was formulated, a search strategy was delimited with descriptors and keywords, as well as the databases and specialized scientific journals were selected. Then, the scope of scientific materials to compose the bibliographic study was retrieved, analyzed and synthesized^{27,28}. The items suggested by the Preferred Reporting Items for Systematic Reviews and

Meta-Analyses - extension for Scoping Reviews²⁹ were considered to structure and enhance the scientific report. There was no need for ethical approval. The guiding question of this study was: what is the role of TLR4 in the pathogenesis of periapical lesions in experimental models?

Eligibility

To contemplate the objective, *in vivo* experimental studies using animal models became eligible. As a criterion, studies whose design, objective and hypothesis directly investigated the role of TLR4 (including *Tlr4*) in the genesis and development of periapical lesions in experimental models were included. There was no restriction on publication period or language, but studies that could not be accessed in full-text were excluded. Therefore, studies in which TLR4 activation or expression was secondary and not directly related to the pathogenesis of periapical lesions, in addition to studies carried out in humans or *in vitro* methods, were excluded from the scope.

Search strategy

The search strategies were elaborated with descriptors extracted from the Medical Subject Headings vocabulary and keywords used in the literature related to the theme, both selected by researchers. A strategy was developed for the databases (#1) and another for the specialized journals (#2), according to the preliminary tests. It was observed that shorter and broader strategies were more efficient in retrieving potentially eligible studies by title and/or abstract. However, both strategies were applied similarly. The *MEDLINE/PubMed*, *Embase*, *Web of Science* and *Google Scholar* databases were selected, as well as the specialized scientific journals *International Endodontic Journal*, *Journal of Endodontics*, and *Australian Endodontic Journal*. Chart 1 presents the search strategies used, including the combination of descriptors and keywords with Boolean operators.

CHART 1 - Search strategy applied in all data sources

Combination of descriptors and keywords	Data sources
#1 (<i>toll-like receptors 4 OR toll like receptor 4 OR TLR4</i>) AND (<i>endodontics OR pulp diseases OR periapical inflammation OR apical periodontitis OR periapical lesion</i>)	MEDLINE/PubMed, Embase, Web of Science and Google Acadêmico
#2 (<i>toll-like receptor 4 OR toll like receptor 4 OR TLR4</i>)	<i>International Endodontic Journal, Journal of Endodontics and Australian Endodontic Journal</i>

Data collection

An independent evaluator carried out the search in all databases and specialized scientific journals. The retrieved references were read in order to verify the inclusion criteria for the scope of the study, including title and abstract (pre-selection), and full-text reading (decision). For each reference, a decision was made between inclusion or exclusion. A second reviewer was consulted when the first reviewer was uncertain, as well as reviewing the eligibility of the references included by the first reviewer for the scope of the study. Duplicates were removed after pre-selection by titles and abstracts. The last data collection was carried out in August 2021. When a reference was deleted after full-text reading, the reason was recorded.

Outcomes

The major outcomes were TLR4-related findings in the pathogenesis of periapical lesions. Therefore, aspects related to the activation and expression of TLR4 or *Tlr4* in periapical tissues were considered, including histopathological, cellular, molecular and genetic evaluations. Secondly, methodological aspects related to experimental models, periapical lesion induction methods and authors' inferences were recorded. Outcomes were evaluated and recorded by the first independent evaluator and checked by the second to minimize divergences and avoid errors. To record the data obtained from the studies for analysis and synthesis, the evaluators used the tables designed to summarize and expose the outcomes related to the objective, filling them out sequentially.

Results

Initially, 356 references were retrieved from databases and specialized scientific journals. At the end of the screening process, four studies³⁰⁻³³ met the eligibility criteria and were selected to compose the scope of the review. Figure 1 shows the study screening flowchart. It is possible to observe that these studies synthesized used rats or mice as experimental models to induce the periapical lesion. Charts 2 and 3 present the main methodological characteristics of the studies included in the scope of the review.

Hou *et al.*³⁰ (2000) induced periapical lesion by pulp exposure of mandibular first molars in C3H/HeJ mice, LPS-hyporesponsive animal model due to *Tlr4* deficiency, the gene responsible for the expression of TLR4. From the authors' perspective, the impact of TLR4 absence on the host's immune response to endodontic

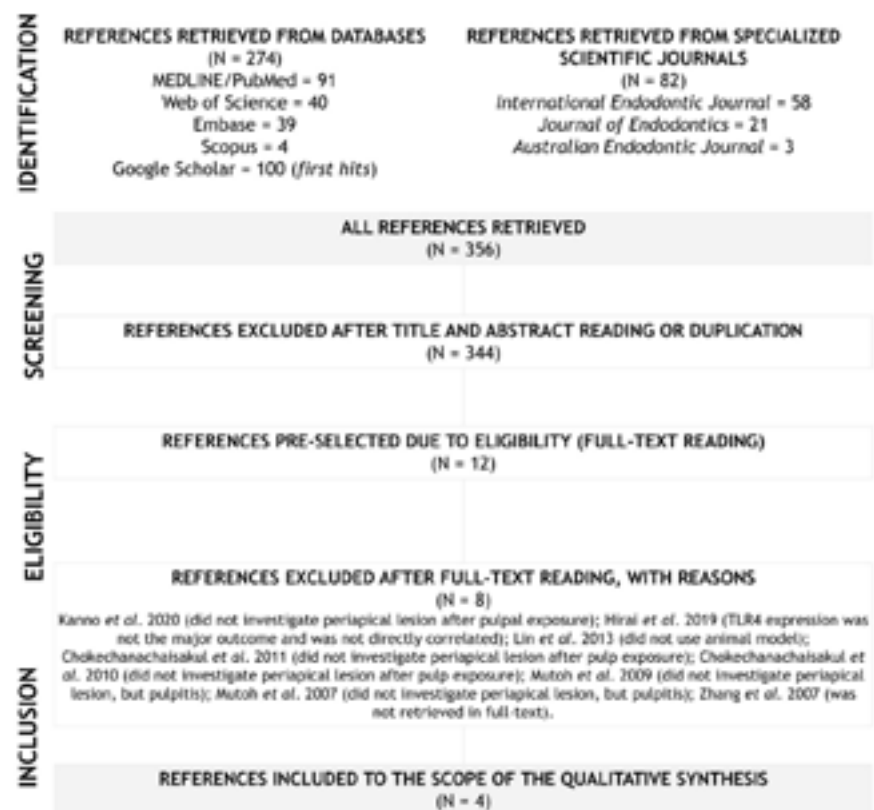


FIGURE 1 · Study screening flowchart

infections was unknown. Then, they decided to compare bone resorption after pulp exposure and infection stimuli between TLR4-deficient and wild-type (C3H/HeOuJ) mice. After pulp tissue exposure, active contamination of the root canals with four endodontic pathogens was performed: *Prevotella intermedia*, *Streptococcus intermedius*, *Fusobacterium nucleatum*, and *Peptostreptococcus micros*. The authors chose to seal the cavity after contamination (resin composite), justifying a possible superinfection by microorganisms in the oral cavity.

CHART 2 - The main methodological characteristics of the studies included in the scope of the review

Authors (year)	Journal	Experimental animal models (n)	Control animal models (n)	Induction of periapical lesion (methods)
Hou <i>et al.</i> (2000) ³⁰	Infection & Immunity	C3H/HeJ mice, 6-8 weeks old (n = 10)	C3H/HeOuJ mice, 6-8 weeks old (n = 10)	Yes (pulp exposure)
Fouad <i>et al.</i> (2001) ³¹	International Endodontic Journal	C3H/HeJ mice, 6-week-old (n = 20)	BALB/c mice, 6-week-old (n = 20)	Yes (pulp exposure)
Rider <i>et al.</i> (2016) ³²	The Anatomical Record	TLR2 knockout mice and TLR2/TLR4 knockout mice, 6-week-old (n = uncertain)	C57BL/6J mice, 6-week-old (n = uncertain)	Yes (pulp exposure)
Liu <i>et al.</i> (2017) ³³	Journal of Endodontics	Wistar rats, unspecified age (n = 42)		Yes (pulp exposure)

CHART 3 - The main methodological characteristics of the studies included in the scope of the review

Authors (year)	Pulp exposure methods	Teeth	Experimental periods	Analysis
Hou <i>et al.</i> (2000) ³⁰	¼ round bur at slow speed, active contamination with endodontic pathogens, with cavity sealing	Mandibular first molars	3 weeks in experimental and control groups	Histomorphometric
Fouad <i>et al.</i> (2001) ³¹	¼ high-speed bur, active contamination with nonspecific pathogens, without cavity sealing	Mandibular first molars	2, 4, 6 and 8 weeks in experimental and control groups	Histopathological; Histomorphometric
Rider <i>et al.</i> (2016) ³²	Not specified, active contamination with endodontic pathogens, unspecified cavity sealing	Mandibular first molars	10 days and 3 weeks in experimental and control groups	Morphometric (micro-computed tomography); Histopathological; Real-time polymerase chain reaction (RT-PCR)
Liu <i>et al.</i> (2017) ³³	¼ round bur, passive contamination, without cavity sealing	Mandibular first molars	0, 7, 14, 21, 28 e 35 days	Histopathological; Morphometric; Immunostaining

After 21 days, all animals were euthanized. As a result, the authors reported that histomorphometric analysis indicated periapical bone resorption in both infected animal models. However, it was observed that TLR4-deficient mice had lower bone resorption (mm^2) when compared to wild-type. Considering all the experiments of the study, the authors suggest that the pro-inflammatory signaling by LPS-TLR4 activation favors the bone resorption of the periapical tissues after the infection of the pulp tissue³⁰.

Fouad and Acosta³¹ (2001) induced periapical lesions by pulp exposure of mandibular first molars in C3H/HeJ and BALB/c (wild-type) mice to compare the progression of periapical lesions. After pulp chamber opening and exposure, an endodontic file previously contaminated with oral microbiota from the gingival sulcus and tongue dorsum was inserted. The cavity sealing was not mentioned and the animals were euthanized after two, four, six or eight weeks of root canal contamination. The cavity was not sealed and the animals were euthanized after two, four, six or eight weeks of root canal contamination. As a result, histopathological and histomorphometric evaluations did not indicate differences in the inflammatory pattern or bone resorption (mm^2) between the different animal models used. The authors suggested that *Tlr4* deficiency may not significantly modulate the pathogenesis of periapical lesions induced by nonspecific microorganisms.

Rider *et al.*³² (2016) considered the relationship between TLR2 and TLR4 in the pathogenesis of periapical lesions. The authors induced periapical lesions by pulp exposure of mandibular first molars in three different experimental animal models (C57BL/6J): wild-type, TLR2 KO, and TLR2/TLR4 double KO (dKO) mice. The aim was to demonstrate how TLR2 and TLR4 interactions can modulate periapical lesions induced by polymicrobial endodontic infection (*Prevotella intermedia*, *Streptococcus intermedius*, *Fusobacterium nucleatum* and *Parvimonas micra*).

Although the authors cite methodological references, the pulp exposure and cavity sealing procedures were not detailed. The animals were euthanized after ten days and three weeks of root canal contamination.

After 21 days, by microtomography analysis, the TLR2 KO mice showed larger periapical lesions (mm^2), while the dKO mice (TLR2 and TLR4) showed a similar size to the wild-type. Histopathological analysis indicated that tissue inflammation was more advanced in TLR2 KO mice after ten days. In addition, after real-time polymerase chain reaction (RT-PCR), TLR4 signaling was higher in TLR2 KO animals at day 21, although with no significant difference compared to wild-type animals. The authors observed an interaction between the two receptors, and pointed out antagonistic roles in the regulation of periapical bone resorption³².

Liu *et al.*³³ (2017) examined TLR4 expression and localization during the development of experimentally induced periapical lesions in *Wistar* rats by pulp exposure of mandibular first molars. The authors measured the number of TLR4-positive cells during the genesis and progression of periapical lesions. There was no active contamination with pathogens and the cavity remained exposed to the oral environment. With the exception of the negative control, the animals were euthanized between seven days and five weeks. As a result, the authors observed that the expression of TLR4 (positive cells) increased progressively in the experimental periods, in parallel with the increase in the periapical lesion size (mm^2), indicating bone resorption. Additionally, among the TLR4-positive cells, several of these were lymphocytes. Therefore, the authors suggested that TLR4 may be associated with the pathogenesis of periapical lesions.

Discussion

Considering the four investigations detailed here and their outcomes, it is essential to recognize that several limitations are present. It is important to highlight that none of them details

the sample size estimation to determine the number of animals needed in the experiment, and no random allocation procedure was described. This perspective is important because comparisons were often made between groups with a small number of animals, such as ten in Hou *et al.*³⁰ (2000), five or ten in Fouad and Acosta³¹ (2001), three to five in Rider *et al.*³² (2016) and seven in Liu *et al.*³³ (2017), as well as using parametric approaches (*e.g.* analysis of variance and *t* tests). Without a sample size estimation based on variability, it is reasonable to question whether the number of animals is plausible for the number of groups compared, as well as whether the use of parametric tests in small samples did not increase the chance of type I error.

Similarly, pulp exposure procedures differed among these studies. In all of them, there was mechanical exposure of the pulp tissue, using burs and endodontic files for exploration. However, three studies carried out active contamination of root canals using endodontic^{30,32} or nonspecific pathogens³¹. Only one study allowed contamination of root canals by exposing the open cavity to the oral environment and its pathogens (passive contamination)³³. In addition, one study performed cavity sealing after root canal contamination³⁰, two studies left the cavities exposed to the oral environment^{31,33} and one study did not specify this conduct³². Anyway, there was destruction of periapical bone tissue, indicating the formation of periapical lesions in all experimental models used.

Another significant limitation observed was the experimental period adopted in these investigations. Two investigations allowed evaluating TLR4-related outcomes at different stages of periapical tissue inflammation progression^{31,33} while two others adopted a restricted evaluation period, limiting their conclusions to them^{30,32}. It was possible to observe important differences in the degree of inflammation and resorption of the periapical tissue when more experimental periods were designed, which should be taken into account when interpreting TLR4-related outcomes.

Regarding animal models, the use of C3H/HeJ mice was observed in two studies. It is known that this strain has been used for over 30 years to study pathological processes related to LPS-TLR4 signal transduction pathway. In this lineage, at the cellular level, lymphocytes, fibroblasts and macrophages do not develop an activation phenotype, being similar to the KO model in the response stimulated by LPS^{30,31}. In the other studies, in addition to wild-type models, there was no use of an exclusively TLR4 KO model, only a double one (TLR2/TLR4)³².

In summary, taking into account all limitations, three studies converge and support the pro-inflammatory role of TLR4-mediated signaling in the pathogenesis of experimental periapical lesions in animal models, inducing inflammation and resorption of bone tissue in the periapical region. Deficient signaling involving TLR4 can attenuate the inflammatory process, reducing the periapical lesion sizes compared to non-deficient controls. The number of TLR4-positive cells tends to increase during the development of periapical lesions^{30,32,33}.

Fouad and Acosta³¹ (2001) diverged from this perspective by reporting that there was no difference in the size of periapical lesions between a TLR4-deficient model and wild-type mice. In addition to the limitations pointed out here, the authors reported a high variability in the periapical lesion sizes from wild-type mice. Furthermore, periapical lesions appeared to reduce after the peak of the fourth week (no statistical analysis properly performed by the authors). Therefore, the authors suggest that an experimental variability can explain the differences between the experimental models, considering that a spontaneous repair is unlikely. It is important to remember that the authors carried out active contamination with non-specific pathogens. However, there are no reports of cavity sealing performed to expose the pulp tissue, allowing its interaction with the oral environment.

In parallel to the TLR4-outcomes, three of the four studies included in the scope of the review evaluated the expression of inflammatory cytokines in experimental models, especially those that modulate bone resorption³⁰⁻³². In Hou *et al.*³⁰ (2000), it was observed that wild-type mice showed significantly increased production of interleukin-1 alfa (IL-1 α), beta (IL-1 β) and interleukin-12 (IL-12) than TLR4-deficient mice after enzyme-linked immunosorbent assay (ELISA) in periapical tissue. In peritoneal macrophages (*in vitro*), a similar outcome was observed for IL-1 α and IL-1 β , although wild-type cells showed marked variability in these variables.

In Rider *et al.*³² (2016), it was observed that *in vitro* macrophages from TLR2 KO mice showed higher expression of IL-1 β compared to wild-type and dKO (TLR2/TLR4), suggesting that suppression of TLR2 signaling may exacerbate TLR4 signaling, as well as supporting increased periapical bone resorption. Lastly, in Fouad and Acosta³¹ (2001), there was no consistent difference in IL-1 α expression between experimental models. The authors maintain that the differences between their outcomes and Hou *et al.*³⁰ (2000) derive from the method, since they did not carry out active contamination with specific endodontic-related pathogens, as well as they did not seal the open cavity in the mouse molars. It is important to consider that TLR4 signaling does not constitute a single tissue inflammation pathway, occurring simultaneously with other regulatory mechanisms, including other Toll-like receptors and their roles, which justifies the expression of pro-inflammatory cytokines to some degree in all models³⁰⁻³².

Discussing these outcomes, it is important to consider that TLR4, before the development of periapical lesions, acts on the pulpal immune response to external agents, such as bacterial components, especially LPS. It has already been shown that odontoblasts and endothelial cells of the blood vessels of the dental pulp express TLR4, including its *mRNA*. *In vitro*, LPS

and bacteria stimulated TLR4 expression, and the suppression of its signaling may interfere with the differentiation of pulpal stem cells, characterizing an important immunological role of these receptors before bone reabsorption in the periapical region^{34,35}. Hirai *et al.*³⁶ (2019) also demonstrated how damage-associated molecular patterns (DAMPs) and PAMPs could activate the TLR4 signaling pathway and trigger an inflammatory response in the periapical tissue.

In a similar perspective, Mutoh *et al.*³⁷ (2007) evaluated the expression of TLR4 in experimentally inflamed pulp tissue (pulpitis). After cavity preparation in BALB/c wild-type mice maxillary molars, evaluated from zero to 72 hours, the authors observed that *mRNA* levels for TLR4 were low compared to TLR2 (30 times higher than TLR4 at nine hours). After this peak, TLR2 expression drastically reduced up to 72 hours, while TLR4 expression was low and constant throughout the period. However, immunohistochemical analysis demonstrated that macrophages and dendritic cells from pulp tissue were stained with anti-TLR4 antibodies in the early stage of experimental pulpitis. In the murine model with severe combined immunodeficiency, with up to 24 hours of dentin exposure after cavity preparation, Mutoh *et al.*³⁸ (2009) observed that TLR2 and TLR4 *mRNA* expression show biphasic patterns, with a peak after three hours of bacterial infection. After the peak, TLR2 and TLR4 *mRNA* expression decreased up to nine hours and increased again after 24 hours. Regarding the cells that expressed TLR4 during pulpal inflammation, they were often macrophages, polymorphonuclear (PMN) and dendritic-like cells.

In experimentally induced furcation lesions of endodontic origin in rat molars, after unsealed pulpotomies, Chokechanachaisakul *et al.*³⁹ (2010) observed that TLR2 and TLR4 expression increased (including its *mRNA*), and positive cells for these receptors were found predominantly in the periodontal ligament below the dentin in the furcation region. Furthermore, TLR4 gene expression

(mRNA) was also demonstrated in pulpal macrophages from LPS-stimulated mice by Chokechanachaisakul *et al.*⁴⁰ (2011). In addition, Lin *et al.*⁴¹ (2013) showed that the cellular expression of TLR2 and TLR4 in inflammatory external root resorption and external cervical resorption were directly correlated with the presence of bacteria. Morphologically, TLR2 or TLR4 positive cells showed similarities with endothelial cells, plasma cells, mononuclear inflammatory cells, and PMNs.

In summary, this evidence supports that Toll-like receptors are often expressed during pulpal immune response, as well as in the development of periapical lesions. However, there is no information about what role TLR4 would play in these pathological processes, such as experimental pulpitis. It was possible to question whether it would also act in a pro-inflammatory way³⁷⁻⁴¹. This evidence would be relevant to comprehensively understanding how TLR4-mediated signaling affects pulpal and periapical tissues during pathological processes, whereas there is no gap with regard to its expression (considering all evidence mentioned). For example, what degree of pulpal inflammation will be seen in a TLR4 KO model after pulp exposure? Will suppression of the TLR4 pathway substantially reduce pulpal inflammation and delay pulpal necrosis when compared to wild-type animal models? Will other signaling pathways be overexpressed in this circumstance, such as TLR2? How does this impact the development of periapical lesions?

Although TLR4 expression continues to be investigated and reported in the literature, both in animal models and in human dental pulp (*ex-vivo* approaches)^{42,43}, to the best of our knowledge, these questions have not been fully elucidated. In periapical lesions, TLR4 signaling is important for the production and release of inflammatory cytokines that induce bone resorption, such as IL-1 α and IL-1 β ^{30,32}. The positive influence of TLR4 signaling on osteoclast differentiation has also been demonstrated in recent studies using animal models^{44,45}.

After this overview, it is also possible to understand that the interface between TLR4 and periapical lesions in animal models is similar to findings in humans (samples of periapical cysts or granulomas), corroborating this evidence. It has already been demonstrated that TLR4 mRNA is significantly expressed in human periapical lesions, both in cases of symptomatic and asymptomatic apical periodontitis, as well as its expression was correlated with the expression of matrix metalloproteinases (MMP-8 and MMP-13), establishing a link between TLR4 expression and other events related to tissue destruction in pathological processes, such as collagen matrix degradation⁴⁶⁻⁴⁸.

On the other hand, in human genetic approaches, polymorphisms in the gene that expresses TLR4 (*Tlr4*) were not associated with a higher risk of developing periapical pathologies when comparing endodontic patients with and without periapical lesion⁴⁹. In the same perspective, it was demonstrated that polymorphisms in this gene were not associated with the presence of apical periodontitis after endodontic treatment, suggesting that these do not influence the response of periapical tissues after clinical interventions¹³, although there is evidence that *Tlr4* mutations may be associated with an increased risk of Gram-negative bacterial infections in intensive care units⁵⁰.

Conclusions

After examining the state of the art, it is possible to conclude that Toll-like receptors can play a significant role in the pathogenesis of periapical lesions in experimental models. Regarding the TLR4, current evidence suggests a pro-inflammatory role, triggering tissue inflammation and bone reabsorption of the periapical tissue by pro-inflammatory cytokines release.

Acknowledgments

The authors would like to thank the Coordination for the Improvement of Higher Education Personnel/Coordenação

de Aperfeiçoamento de Pessoal de Nível Superior (CAPES) for granting master's (Clara Marina Pereira Cavalcanti da Silva) and doctoral (Ricardo Barbosa Lima) scholarships.

References

- 1- Sjögren U, Figdor D, Persson S, Sundqvist G. Influence of infection at the time of root filling on the outcome of endodontic treatment of teeth with apical periodontitis. *Int Endod J.* 1997; 30(5): 297-306. doi: 10.1046/j.1365-2591.1997.00092.x.
- 2- Stashenko P, Teles R, D'Souza R. Periapical inflammatory responses and their modulation. *Crit Rev Oral Biol Med.* 1998; 9(4): 498-521. doi: 10.1177/10454411980090040701.
- 3- Colić M, Gazivoda D, Vučević D, Majstorović I, Vasilijić S, Rudolf R, *et al.* Regulatory T-cells in periapical lesions. *J Dent Res.* 2009; 88(11): 997-1002. doi: 10.1177/0022034509347090.
- 4- Duncan HF, Cooper PR. Pulp innate immune defense: translational opportunities. *J Endod.* 2020; 46(9S): S10-S18. doi: 10.1016/j.joen.2020.06.019.
- 5- Safavi KE, Nichols FC. Effect of calcium hydroxide on bacterial lipopolysaccharide. *J Endod.* 1993; 19(2): 76-8. doi: 10.1016/S0099-2399(06)81199-4.
- 6- Silva LAB, Nelson-Filho P, Leonardo MR, Rossi MA, Pansani CA. Effect of calcium hydroxide on bacterial endotoxin in vivo. *J Endod.* 2002; 28(2): 94-8. doi: 10.1097/00004770-200202000-00011.
- 7- Leonardo MR, Silva RAB, Assed S, Nelson-Filho P. Importance of bacterial endotoxin (LPS) in endodontics. *J Appl Oral Sci.* 2004; 12(2): 93-8. doi: 10.1590/s1678-77572004000200002.
- 8- Queiroz AM, Arid J, Nelson-Filho P, Lucisano MP, Silva RAB, Sorgi CA, *et al.* Correlation between bacterial endotoxin levels in root canals of primary teeth and the periapical lesion area. *J Dent Child (Chic).* 2016; 83(1): 9-15.
- 9- Wang Y, Zhang S, Li H, Wang H, Zhang T, Hutchinson MR, *et al.* Small-molecule modulators of Toll-like receptors. *Acc Chem Res.* 2020; 53(5): 1046-1055. doi: 10.1021/acs.accounts.9b00631.
- 10- Takeda K, Kaisho T, Akira S. Toll-like receptors. *Annu Rev Immunol.* 2003;21:335-76. doi: 10.1146/annurev.immunol.21.120601.141126.
- 11- Mukherjee S, Huda S, Babu SPS. Toll-like receptor polymorphism in host immune response to infectious diseases: a review. *Scand J Immunol.* 2019; 90(1): e12771. doi: 10.1111/sji.12771.
- 12- Van Maren WW, Jacobs JF, Vries IJ, Nierkens S, Adema GJ. Toll-like receptor signalling on Tregs: to suppress or not to suppress? *Immunology.* 2008; 124(4): 445-52. doi: 10.1111/j.1365-2567.2008.02871.x.

- 13 - Rôças IN, Siqueira Jr. JF, Del Aguila CA, Provenzano JC, Guilherme BP, Gonçalves LS. Polymorphism of the CD14 and TLR4 genes and post-treatment apical periodontitis. *J Endod.* 2014; 40(2): 168-72. doi: 10.1016/j.joen.2013.10.006.
- 14 - Rovai EDS, Matos FS, Kerbauy WD, Cardoso FGDR, Martinho FC, Oliveira LD, *et al.* Microbial profile and endotoxin levels in primary periodontal lesions with secondary endodontic involvement. *Braz Dent J.* 2019; 30(4): 356-362. doi: 10.1590/0103-6440201902471.
- 15 - Kawai T, Akira S. The role of pattern-recognition receptors in innate immunity: update on Toll-like receptors. *Nat Immunol.* 2010; 11(5): 373-84. doi: 10.1038/ni.1863.
- 16 - Kawai T, Akira S. Toll-like receptors and their crosstalk with other innate receptors in infection and immunity. *Immunity.* 2011; 34(5): 637-50. doi: 10.1016/j.immuni.2011.05.006.
- 17 - Ullah MO, Sweet MJ, Mansell A, Kellie S, Kobe B. TRIF-dependent TLR signaling, its functions in host defense and inflammation, and its potential as a therapeutic target. *J Leukoc Biol.* 2016; 100(1): 27-45. doi: 10.1189/jlb.2RI1115-531R.
- 18 - Silva RAB, Ferreira PD, Rossi A, Nelson-Filho P, Silva LA. Toll-like receptor 2 knockout mice showed increased periapical lesion size and osteoclast number. *J Endod.* 2012; 38(6): 803-13. doi: 10.1016/j.joen.2012.03.017.
- 19 - Silva RAB, Nelson-Filho P, Lucisano MP, Rossi A, Queiroz AM, Silva LAB. MyD88 knockout mice develop initial enlarged periapical lesions with increased numbers of neutrophils. *Int Endod J.* 2014; 47(7): 675-86. doi: 10.1111/iej.12204.
- 20 - Barreiros D, Nelson-Filho P, Paula-Silva FWG, Oliveira KMH, Lucisano MP, Rossi A, *et al.* MMP2 and MMP9 are associated with apical periodontitis progression and might be modulated by TLR2 and MyD88. *Braz Dent J.* 2018; 29(1): 43-47. doi: 10.1590/0103-6440201801731.
- 21 - Ain QU, Batool M, Choi S. TLR4-targeting therapeutics: structural basis and computer-aided drug discovery approaches. *Molecules.* 2020; 25(3): 627. doi: 10.3390/molecules25030627.
- 22 - Ciesielska A, Matyjek M, Kwiatkowska K. TLR4 and CD14 trafficking and its influence on LPS-induced pro-inflammatory signaling. *Cell Mol Life Sci.* 2021; 78(4): 1233-1261. doi: 10.1007/s00018-020-03656-y.
- 23 - Zhan X, Stamova B, Sharp FR. Lipopolysaccharide associates with amyloid plaques, neurons and oligodendrocytes in Alzheimer's disease brain: a review. *Front Aging Neurosci.* 2018; 10:42. doi: 10.3389/fnagi.2018.00042.
- 24 - Li XP, Liu P, Li YF, Zhang GL, Zeng DS, Liu DL. LPS induces activation of the TLR4 pathway in fibroblasts and promotes skin scar formation through collagen I and TGF- β in skin lesions. *Int J Clin Exp Pathol.* 2019; 12(6): 2121-2129.

- 25 - Shen S, Wang K, Zhi Y, Shen W, Huang L. Gypenosides improves nonalcoholic fatty liver disease induced by high-fat diet induced through regulating LPS/TLR4 signaling pathway. *Cell Cycle*. 2020; 19(22): 3042-3053. doi: 10.1080/15384101.2020.1829800.
- 26 - Afroz R, Tanvir EM, Tania M, Fu J, Kamal MA, Khan MA. LPS/TLR4 pathways in breast cancer: insights into cell signalling. *Curr Med Chem*. 2022; 29(13): 2274-2289. doi: 10.2174/0929867328666210811145043.
- 27 - Peters MD, Godfrey CM, Khalil H, McInerney P, Parker D, Soares CB. Guidance for conducting systematic scoping reviews. *Int J Evid Based Healthc*. 2015;13(3): 141-6. doi: 10.1097/XEB.000000000000050.
- 28 - Lockwood C, Santos KB, Pap R. Practical guidance for knowledge synthesis: scoping review methods. *Asian Nurs Res (Korean Soc Nurs Sci)*. 2019; 13(5):287-294. doi: 10.1016/j.anr.2019.11.002.
- 29 - Tricco AC, Lillie E, Zarin W, O'Brien KK, Colquhoun H, Levac D, *et al*. PRISMA Extension for Scoping Reviews (PRISMA-ScR): checklist and explanation. *Ann Intern Med*. 2018; 169(7): 467-473. doi: 10.7326/M18-0850.
- 30 - Hou L, Sasaki H, Stashenko P. Toll-like receptor 4-deficient mice have reduced bone destruction following mixed anaerobic infection. *Infect Immun*. 2000; 68(8): 4681-7. doi: 10.1128/IAI.68.8.4681-4687.2000.
- 31 - Fouad AF, Acosta AW. Periapical lesion progression and cytokine expression in an LPS hyporesponsive model. *Int Endod J*. 2001; 34(7): 506-13. doi: 10.1046/j.1365-2591.2001.00423.x.
- 32 - Rider D, Furusho H, Xu S, Trachtenberg AJ, Kuo WP, Hirai K, *et al*. Elevated CD14 (cluster of differentiation 14) and toll-like receptor (TLR) 4 signaling deteriorate periapical inflammation in TLR2 deficient mice. *Anat Rec (Hoboken)*. 2016; 299(9): 1281-92. doi: 10.1002/ar.23383.
- 33 - Liu L, Deng J, Ji Q, Peng B. High-mobility group box 1 is associated with the inflammatory infiltration and alveolar bone destruction in rats experimental periapical lesions. *J Endod*. 2017; 43(6): 964-969. doi: 10.1016/j.joen.2016.11.014.
- 34 - Jiang HW, Zhang W, Ren BP, Zeng JF, Ling JQ. Expression of toll like receptor 4 in normal human odontoblasts and dental pulp tissue. *J Endod*. 2006; 32(8): 747-51. doi: 10.1016/j.joen.2006.01.010.
- 35 - Liu Y, Gao Y, Zhan X, Cui L, Xu S, Ma D, *et al*. TLR4 activation by lipopolysaccharide and *Streptococcus mutans* induces differential regulation of proliferation and migration in human dental pulp stem cells. *J Endod*. 2014; 40(9): 1375-81. doi: 10.1016/j.joen.2014.03.015.
- 36 - Hirai K, Furusho H, Kawashima N, Xu S, de Beer MC, Battaglino R, *et al*. Serum amyloid A contributes to chronic apical periodontitis via TLR2 and TLR4. *J Dent Res*. 2019; 98(1): 117-125. doi: 10.1177/0022034518796456.

- 37** - Mutoh N, Tani-Ishii N, Tsukinoki K, Chieda K, Watanabe K. Expression of toll-like receptor 2 and 4 in dental pulp. *J Endod.* 2007; 33(10): 1183-6. doi: 10.1016/j.joen.2007.05.018.
- 38** - Mutoh N, Watabe H, Chieda K, Tani-Ishii N. Expression of Toll-like receptor 2 and 4 in inflamed pulp in severe combined immunodeficiency mice. *J Endod.* 2009; 35(7): 975-80. doi: 10.1016/j.joen.2009.04.005.
- 39** - Chokechanachaisakul U, Kaneko T, Okiji T, Kaneko R, Kaneko M, Kawamura J, *et al.* Increased gene expression of Toll-like receptors and antigen-presenting cell-related molecules in the onset of experimentally induced furcation lesions of endodontic origin in rat molars. *J Endod.* 2010; 36(2): 251-5. doi: 10.1016/j.joen.2009.10.005.
- 40** - Chokechanachaisakul U, Kaneko T, Yamanaka Y, Kaneko R, Katsube K, Kobayashi H, Nör JE, Okiji T, Suda H. Gene expression analysis of resident macrophages in lipopolysaccharide-stimulated rat molar pulps. *J Endod.* 2011; 37(9): 1258-63. doi: 10.1016/j.joen.2011.06.010.
- 41** - Lin YP, Love RM, Friedlander LT, Shang HF, Pai MH. Expression of Toll-like receptors 2 and 4 and the OPG-RANKL-RANK system in inflammatory external root resorption and external cervical resorption. *Int Endod J.* 2013; 46(10): 971-81. doi: 10.1111/iej.12088.
- 42** - Hasan A, Roome T, Wahid M, Ansari SA, Khan JA, Jilani SNA, *et al.* Expression of Toll-like receptor 2, Dectin-1, and Osteopontin in murine model of pulpitis. *Clin Oral Investig.* 2023; 27(3): 1177-1192. doi: 10.1007/s00784-022-04732-2.
- 43** - Hasan A, Roome T, Wahid M, Ansari SA, Akhtar H, Jilani SNA, *et al.* Gene expression analysis of toll like receptor 2 and 4, Dectin-1, Osteopontin and inflammatory cytokines in human dental pulp ex-vivo. *BMC Oral Health.* 2022; 22(1): 563. doi: 10.1186/s12903-022-02621-4.
- 44** - Davis HM, Valdez S, Gomez L, Malicky P, White FA, Subler MA, *et al.* High mobility group box 1 protein regulates osteoclastogenesis through direct actions on osteocytes and osteoclasts in vitro. *J Cell Biochem.* 2019; 120(10): 16741-16749. doi: 10.1002/jcb.28932.
- 45** - Zhou CC, Xu RS, Wu ZP, Zhang ZW, Yuan Q, Zou SJ, *et al.* Osteogenesis, osteoclastogenesis and their crosstalk in lipopolysaccharide-induced periodontitis in mice. *Chin J Dent Res.* 2021; 24(1): 33-39. doi: 10.3290/j.cjdr.b1105871.
- 46** - Oliveira RCM, Beghini M, Borges CR, Alves PM, Araújo MS, Pereira SA, *et al.* Higher expression of galectin-3 and galectin-9 in periapical granulomas than in radicular cysts and an increased toll-like receptor-2 and toll-like receptor-4 expression are associated with reactivation of periapical inflammation. *J Endod.* 2014; 40(2): 199-203. doi: 10.1016/j.joen.2013.10.031.
- 47** - Leonardi R, Perrotta RE, Loreto C, Musumeci G, Crimi S, Santos JN, *et al.* Toll-like receptor 4 expression in the epithelium of inflammatory

periapical lesions. An immunohistochemical study. *Eur J Histochem.* 2015; 59(4): 2547. doi: 10.4081/ejh.2015.2547.

- 48 - Fernández A, Cárdenas AM, Astorga J, Veloso P, Alvarado A, Merino P, Pino D, Reyes-Court D, Hernández M. Expression of Toll-like receptors 2 and 4 and its association with matrix metalloproteinases in symptomatic and asymptomatic apical periodontitis. *Clin Oral Investig.* 2019; 23(12): 4205-4212. doi: 10.1007/s00784-019-02861-9.
- 49 - Özan Ü, Ocak Z, Özan F, Oktay EA, Toptaş O, Şahman H, *et al.* Association of Toll-like receptors 2, 3, and 4 genes polymorphisms with periapical pathosis risk. *Med Oral Patol Oral Cir Bucal.* 2016; 21(4): e408-12. doi: 10.4317/medoral.21081.
- 50 - Agnese DM, Calvano JE, Hahm SJ, Coyle SM, Corbett SA, Calvano SE, *et al.* Human toll-like receptor 4 mutations but not CD14 polymorphisms are associated with an increased risk of Gram-negative infections. *J Infect Dis.* 2002; 186(10): 1522-5. doi: 10.1086/344893.

O papel do receptor do tipo toll 4 na patogênese das lesões periapicais em modelos experimentais: uma revisão de escopo

Resumo

Objetivo: Descrever o estado da arte sobre o papel do receptor do tipo Toll 4 na patogênese de lesões periapicais em modelos experimentais. **Métodos:** Foi realizado um procedimento sistematizado de busca para alcançar a literatura disponível acerca do tema em bases de dados e periódicos científicos especializados: MEDLINE, Embase, Web of Science, Google Acadêmico, International Endodontic Journal, Journal of Endodontics e Australian Endodontic Journal. **Resultados:** Foram incluídos quatro estudos ao escopo da revisão. Do ponto de vista operacional, todos os estudos induziram a formação de lesões periapicais pela contaminação dos canais radiculares. Os modelos experimentais foram ratos e camundongos, incluindo animais selvagens ou que apresentavam mutações ou knockout no gene Tlr4. Em termos gerais, a sinalização do TLR4 esteve associada à inflamação e reabsorção do tecido periapical em camundongos e ratos selvagens. A expressão deste receptor tende a aumentar ao longo da patogênese de lesões periapicais. Em camundongos deficientes para TLR4, desfechos controversos foram observados. Em um modelo hiporresponsivo de lipopolissacarídeo devido à mutação em Tlr4, há evidência de redução da reabsorção óssea periapical em um estudo. Entretanto, um estudo não observou estas diferenças. Os estudos atuais apresentam limitações significativas para consolidar tais desfechos, incluindo o número de animais nos experimentos, análises estatísticas e períodos experimentais utilizados. **Conclusão:** É possível concluir que TLR4 pode atuar significativamente na gênese e no desenvolvimento de lesões periapicais em modelos experimentais.

PALAVRAS-CHAVE: Endodontia; Doenças Periapicais; Receptor 4 Toll-Like.

How to cite this paper

Lima RB, Silva A, Silva CMPC, Nelson-Filho P, Da Silva LAB, Silva RAB. The role of toll-like receptor 4 in the pathogenesis of periapical lesions in experimental models: a scoping review. Rev Odontol Bras Central 2024; 33(92): 81-101. DOI: 10.36065/robrac.v33i92.1725