






Photobiomodulation and its benefits in the dental trauma protocols for children: a case report

Andreza Mascarenhas Batista de JESUS¹; Marina Silveira GOMES¹; Priscila Rubia MANIERI¹; Raiane Rosa de Souza LOPES²; Alessandra Castro ALVES³

1 - Undergraduation student in dentistry from the Federal University of Bahia; **3** - Bachelor of Science in Health from Federal University of Bahia; Undergraduation student in dentistry from the Federal University of Bahia; **3** - Specialist and Master in Pediatric Dentistry. PhD in Microbiology and Immunology. Associate Professor of Cariology and Pediatric Dentistry. Department of Social and Pediatric Dentistry at Federal University of Bahia (UFBA). Adjunct Professor of Pediatric Dentistry at State University of Feira de Santana (UEFS). Coordinator and professor of the Research and Extension Center for child and adolescent Dental Trauma at the Federal University of Bahia (UFBA).

Abstract

The classification of traumatic dental injuries can involve teeth, supporting structures, or gingival and oral mucosa. The therapeutic use of lasers has become standard practice in many medical fields, but dental traumatology is not yet one of them. This case report relates dental trauma of a 36-month-old girl referred to the Dental Trauma Center for Children and Adolescents in a University dental clinic (Brazil). Her fall down the stairs at home resulted in face trauma, avulsion of a primary incisor and soft tissue injuries. The mother reported pain and inflammation of the lacerated lip. After examination, a low-level laser was applied to ulcerated lip and gingival tissues. The protocol was punctual and continuous application at 660nm, 1J/point every 48 hours. The low-level laser biomodulation capacity provided complete tissue healing after 14 days of sessions. Clinical trials are suggested. Conservative treatment in this case of severe soft-tissue injuries into a baby showed a clinically satisfactory result. Minimal intervention was also important to minimize possible psychological side effects of surgical dental therapy. Low-level lasers are an excellent alternative therapy for children, because of their analgesic/anti-inflammatory and biomodulatory effects.

KEYWORDS: Photobiomodulation; Pediatric dentistry; Dental Trauma; Soft tissue injuries; Case report.



Copyright © 2023 Revista Odontológica do Brasil Central · This work is licensed under a Creative Commons Attribution-NonCommercial-ShareAlike 4.0 International License(CC BY-NC-SA 4.0)

Received: 22/11/21
Accepted: 30/01/23
Published: 17/07/23

DOI: 10.36065/robrac.v32i91.1581

CORRESPONDING AUTHOR

Alessandra Castro Alves

Estácio Gonzaga Street, 28 apto 801 – Horto Florestal, Salvador (Bahia), Brazil - Cep: 40295-020.

Email: acaastroalves@hotmail.com

Phone: (+55) 71 987966377

Introduction

Dental trauma is an impact causing injury to teeth and both hard and soft tissues in the oral cavity; it requires urgent attention. Dental injuries occur more frequently with young people (17-50%) and children (9-40%). The antero-superior region is the most prevalent, and the central incisors are the most affected^{1,2}. Some variables have higher risk, especially patients with attention deficit/hyperactivity, aggressive behavior, increased overjet, anterior open bite, lack of lip sealing and high body mass index³.

Consequences of traumatic injuries to dental and supporting tissues include fractures/subluxations and avulsions. Trauma to soft tissues can cause laceration, contusion and abrasion, commonly affecting mucosa, lips and gums. Laceration is tearing of tissue caused by sharp objects. Comparatively, contusion is a bruise caused by blunt objects, whereas abrasion is a wound caused by removal of the superficial layer of tissue⁴, especially soft tissue (over 50% prevalence²).

Guidelines for minimal intervention are constantly changing with emergence of new developments⁵. Low-level lasers with red and infrared electromagnetic spectrum (620-904nm) can harness anti-inflammatory, analgesic, healing and biomodulatory action. This biomodulatory action mediates various metabolic processes through its activation or inhibition, and promotes varied therapeutic effects such as morphodifferentiation and cell proliferation, tissue neof ormation and cell regeneration. Thus, the laser stimulates the mitotic cycle, favoring the processes of neovascularization and formation of granulation tissue, which are responsible for tissue repair (6). This therapy can be performed on pediatric patients with excellent results, based on a minimal intervention approach⁷. This case report refers to a child who suffered injury to the face, sought care at the NEPTi Center, and ultimately underwent laser therapy.

Case report

A 36-month-old female preschooler was admitted to the NEPTi Center with her mother, referred by a referral hospital. The girl's mother signed an informed consent form. The main complaint was face trauma after falling down the stairs at home two days earlier. Admission to the hospital left the patient frightened and crying. The mother reported that a radiograph of the girl's face had already been performed, and first aid consisted of an anti-septic applied to the lip. The prescribed medication was ibuprofen (50mg/ml) administered orally. The mother presented an updated vaccination card.

No systemic disease was related. The patient hurt her mouth when falling from height. The primary maxillary left central incisor fell out during the accident, according to the mother, and the lip was cut, with bleeding.

Exams indicated laceration of lower lip, and abrasions around lower and upper lips (Figure 1). The patient resisted against cleaning of the affected area, and the mother confirmed this as a constant problem. Antisepsis consisted of saline solution and chlorhexidine. On-site laser application used knee-to-knee for stabilization. Radiographs were taken of the lower lip to detect possible foreign bodies/dental fragments, and of the upper anterior region. Lip radiographs showed no radiopacities. The upper arch showed an empty socket confirming the avulsion (Figure 2).

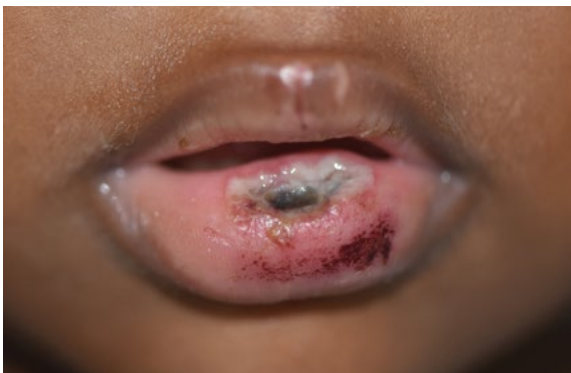

FIGURE 1 - Extra buccal evaluation showing lesions in soft tissues of the type of abrasion in the lower and upper lips. Extensive lower lip laceration in a 36-month-old girl, 48 hours after accident.

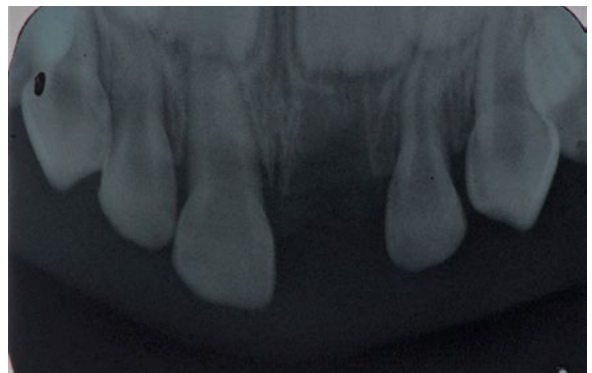


FIGURE 2 - Diagnostic radiography, modified occlusal of the upper arch, showing the absence of the deciduous left upper central incisor in the 36-month-old female child 48 hours after the accident.

The oral cavity showed gingival inflammation, mobility of primary maxillary right central incisor, and biofilm on teeth. Neither prophylaxis nor intraoral photographs were undertaken, owing to the child's young age. The mother received guidance regarding importance of eating liquid and pasty foods. Strict hygiene practices were recommended using chlorhexidine and soft toothbrush.

Red light laser (DMC® Therapy TX, São Paulo/SP, Brazil) was used with punctual and continuous application at 660nm (100mW/90-240V), and 1J/point with fluence of 35J/cm² for 10 seconds. The device was positioned perpendicularly to the labial tubercle, at five points 1 cm apart. In cases of superficial tissue injury, according to the protocol of the Federal University of Goiás (UFG), the red laser acts from 35 to 71 J/cm² (1.0-2.0J) per point, along the wound, one point beside on the other, every 24 hours⁸. For the present clinical case, the use of the laser was recommended once a week for 3 weeks, that is, three laser applications, concomitantly with antimicrobials. However, in just 2 weeks all soft tissue injuries had healed. In addition, the protocol was changed due to the lack of availability of the person responsible for the patient to take her every 24 hours.

The teeth had biofilm and gingival inflammation seven days after trauma. The gingival area of the maxillary right central incisor was abraded, exposing the periosteum (Figure 3), and the mother reported a recurrent accident that led to its avulsion, 15 days after the first trauma. The lip was healthier and healed (Figure 4). The follow-up consisted of low-level laser applications for two months.

Discussion

The child suffered trauma at home, leading to avulsion of primary maxillary left central incisor and soft tissue injuries. Trauma is very common with children 1-3 years of age³. Infants start running, jumping, and acting quickly and unpredictably at 2-3

years. They crave independence, but lack motor coordination. Greater protection, supervision and discipline are certainly needed at home, where most accidents occur⁹. This case report showed substantial vulnerability resulting from socioeconomic difficulties together with unblocked spaces, and unprotected stairs, windows and outside environments. Falls from height affecting the face are frequent^{9,10}.

Lacerations and abrasions are classified together with bruises. Prevalence rates above 50% occur in soft tissues next to primary teeth^{2,11}. Lacerations are associated with more intense trauma and depend on its direction. Abrasive and contusive injuries are common for upper lip, and lacerations, for lower lip¹¹. The soft tissue injury of this patient was severe and resulted in major lower lip laceration and abrasions to upper and lower lips and gingival tissue. The report included the parents' expectations when they sought the hospital after the fall. Many parents are moved to urgency when there is severity, such as hemorrhaging¹¹. Extensive laceration of the lip with deep connective exposure caused abundant arterial bleeding and family stress. In an emergency, the lesion would be debrided to detect possible foreign bodies and washed with a jet of saline, the blood would be stopped, and the wound, sutured. In the event that care-giving efforts may be inconclusive, well-conducted exams should be

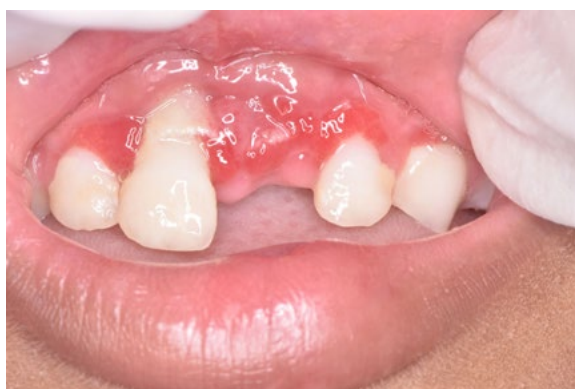

FIGURE 3 - Photography at the second visit, 14 days after the trauma. It is possible to observe the erythematous aspect of the free and inserted marginal gingiva and exposure of the root alveolar bone tissue of the central incisor.

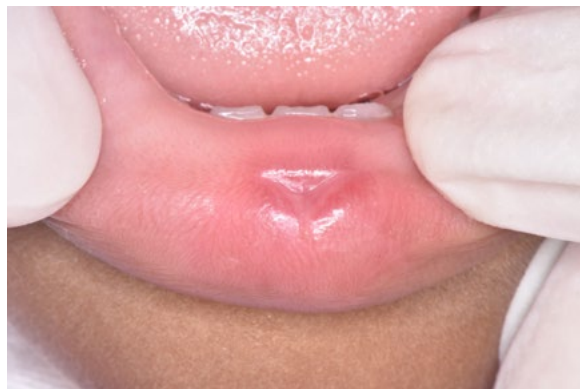

FIGURE 4 - Healing of the lower lip 14 days after the first laser therapy session, 16 days after the traumatic injury.

reinforced to ensure effective treatment. Ultimately, the child had been referred from another public service, thus postponing diagnosis and treatment for over 48 hours.

Attention to lacerations in the cavity or peribuccal region should consider the severity and probability of contamination. It is imperative to check vaccination status for tetanus immunization¹², antibiotic coverage and sutures. Hygiene procedures and antiseptics were performed at dental clinic. Suture was no longer relevant given the granulation tissue. However, healing was quick, and improved the child's appearance, pain sensitivity and discomfort.

Radiographs should be taken in dental avulsions⁵. The occlusal technique was performed comfortably. Supporting tissues and adjacent teeth were visualized. The technique was performed by confirming the avulsion, and there were no fractures. Avulsion is common among most serious and frequent traumas to deciduous teeth, owing to bone plasticity¹³. These cases must be followed up until the successors erupt, owing to possible complications⁵.

Dental trauma places great physical and emotional stress on both children and parents and can compromise treatments. In emergencies, the child's extent of cooperation and young age must be borne in mind. Laser therapy was the indicated procedure to allow biosafe care and secure the child's confidence. Minimum intervention increases the chances of success when the child cooperates¹⁴, and this is easier to do with laser therapy, as opposed to using sharp and rotating instruments^{6,7}. As such, it contributed to its acceptance, and further urged the mother to improve the patient's hygiene practices and diet.

A laser's red light can reach inflamed keratinized tissues, and their repair is driven by biomodulation with energy absorption that increases the metabolism^{1,6,7}. Mitosis, vasodilation, angiogenesis, keratinocyte proliferation, TGF- β 1 and cell propagation

trigger hemostasis and anti-inflammatory action^{6,15}. The repair process ranges according to wavelength and power. The values used on the patient^{8,16,17,18}, helped speed up healing to 14 days, and the child's labile cells showed high proliferation¹⁵. Lasers have become an alternative and adjunct to analgesics and anti-inflammatories, because they can reduce and/or replace consumption of these drugs and have a similar effect^{1,7}.

A study on the effects of laser photobiomodulation on the repair of skin lesions in an animal model found the effects of the 658nm, 830nm and 904nm laser on healing, indicating that laser irradiation was capable of stimulating tissue repair and with better results for the wavelength of 658 nm. The energy density values applied are variable. In that same study, low energy density (3 J/cm²) compared to higher energy (30 J/cm²) demonstrated that both are effective in neovascularization and in increasing the number of cells¹⁸. Another study on the use of low-power laser to aid in the healing of lesions in rats, with a wavelength of 660 nm, power 100 mW and dose 10 J/cm², demonstrated more epithelialization, providing greater healing¹⁶.

A similar study on the use of the ingaalp laser with a wavelength of 660 nm in the healing of cutaneous wounds in diabetic rats, also showed that the low power laser (660 nm) is capable of increasing the amount of macrophages and collagen fibers, helping in the process of tissue repair¹⁹. That is, such studies corroborate the use of laser in this case, which was of a wavelength of 660 nm, 100 mW, but with an energy density of 35 J/cm². However, it is known that energy density values can be variable. Despite the studies mentioned being on skin lesions in animals, they can still be used as a parameter for the present study, which was used in soft tissue lesions due to dental trauma.

Trauma can affect a child's self-esteem, inefficiency in masticatory function and phonetics. Informing parents about how to prevent accidents and to care for resulting injuries should include mentioning risk factors^{20,21}. The mother joined the

dental trauma center network, where treatment is humanized. An esthetic functional space maintainer will be placed, and the patient will be followed up until eruption of permanent successor teeth.

Conclusion

- a. Low-level lasers have high resolution for improved treatment of soft-tissue injuries.
- b. Low-level lasers are an excellent alternative therapy for children, because of their analgesic/anti-inflammatory and biomodulatory effects.
- c. More studies are warranted to ensure a reliable protocol in using low-level lasers.

References

- 1- Caprioglio C, Olivi G, Genovese MD. Lasers in dental traumatology and low level laser therapy (LLLT). *Eur Arch Paediatr Dent*. 2011; 12(2): 79-84.
- 2- Figueiró AP, Henzel LT, Posser RU, Silva MP, Rosa TS, Costa VPP. Prevalence of soft tissue injuries in patients assisted in a specialized treatment center for dental trauma. *RFO UPF*. 2016; 21(3): 401-406.
- 3- Born CD, Jackson TH, Koroluk LD, Divaris K. Traumatic dental injuries in preschool-age children: prevalence and risk factors. *Clin Exp Dent Res*. 2019; 5(2): 151-159.
- 4- Soares TRC, Barbosa ACU, Oliveira SNS, Oliveira EM, Risso PA, Maia LC. Prevalence of soft tissue injuries in pediatric patients and its relationship with the quest for treatment. *Dent Traumatol*. 2016; 32(1): 48-51.
- 5- Day PF, Flores MT, O'Connell AC, Abbott PV, Tsilingaridis G, Fouad AF et al. International of dental traumatology guidelines for the management of traumatic dental injuries: 3. Injuries in the primary dentition. *Dent Traumatol*. 2020; 36(4): 343-59.
- 6- Henriques ACG, Cazal C, Castro JFL. Low intensity laser therapy effects on cell proliferation and differentiation: review of the literature. *Rev Col Bras Cir*. 2010; 37(4): 295-302.
- 7- Oliveira FAM, Martins MT, Ribeiro MA, Mota PHA, Paula MVQ. Indications and treatments of low level laser therapy in dentistry: a systematic review of the literature. *HU Revista*. 2018; 44(1): 85-96.

- 8 - Moreira FCL, Verás LG, Moreira SC, Roriz VM. Manual prático para uso dos lasers na odontologia [Ebook]. Cegraf UFG. 2020; (1):21.
- 9 - Lam R. Epidemiology and outcomes of traumatic dental injuries: a review of the literature. *Aust Dent J* 2016;61:4-20.
- 10 - Zaleckiene V, Peciuliene V, Brukiene V, Drukteinis S. Traumatic dental injuries: etiology, prevalence and possible outcomes. *Stomatologia* 2014; 16(1): 7-14.
- 11 - Vuletić M, Škaričić J, Batinjan G, Trampuš Z, Čuković Bagić I, Jurić H. A retrospective study on traumatic dental and soft-tissue injuries in preschool children in Zagreb, Croatia. *Bosn J Basic Med Sci.* 2014; 14(1): 12-15.
- 12 - Brasil. Ministério da Saúde. Secretaria de Vigilância em Saúde. Departamento de Vigilância Epidemiológica. Infectious and parasitic diseases: pocket guide. 6. ed. Brasília: Ministério da Saúde; 2005. 320 p.
- 13 - Kramer PF, Onetto J, Flores MT, Borges TS, Feldens CA. Traumatic dental injuries in the primary dentition: a 15-year bibliometric analysis of dental traumatology. *Dent Traumatol.* 2016; 32(5): 341-346.
- 14 - Galui S, Pal S, Mahata S, Saha S, Sarkar S. Laser and its ude in pediatric dentistry: A review of literature and a recent update. *Int J Pedod Rehabil.* 2019; 4(1): 1-5.
- 15 - Neena IE, Poornima P, Edagunji G, Roopa KB, Bharath KP. Lasers in pediatric dentistry: A review. *ICDMR* 2015.
- 16 - Calisto FCFS, Calisto SLS, Souza AP, França CM, Ferreira APL, Moreira MB. Use of low-power laser to assist the healing of traumatic wounds in rats. *Acta Cir Bras.* 2015; 30(3): 204-208.
- 17 - Lima FJC, Neto OBO, Barbosa FT, Galvão AMN, Ramos FWS, Lima CCF, Rodrigues CFS. Is there a protocol in experimental skin wounds in rats using low-level diode laser therapy (LLDLT) combining or not red and infrared wavelenghts? Systematic review. *Lasers Med Sci.* 2016. 31 (4): 779-87.
- 18 - Barbosa LS, Parisi JR, Viana LC, Carneiro MB, Silva JRT, Silva ML, Novaes RD, Sousa L. The photobiomodulation (658, 830 and 940nm) on wound healing in histomorphometric analysis. *Fisioter Mov.* 2020; 33: 1-10.
- 19 - Carvalho PTC, Silva IC, Reis FA, Pereira DM, Aydos RD. Influence of ingaalp laser (660nm) on the healing of skin wounds in diabetic rats. *Acta Cirúrgica Brasileira.* 2010; 25(1): 71-79.
- 20 - Kaur P, Singh S, Mathur A, Makkar DK, Aggarwal VP, Batra M, Sharma A, Goyal N. Impact of dental disorders and its influence on self esteem levels among adolecents. *journal of clinical and diagnostic research. J Clin Diagn Res.* 2017; 11(4): ZC5-ZC8.
- 21 - Fernandes JRL, Godoi LA, Buard RD, Marques FR, Portugal MEG, Dallendone M. Traumatismo Dentoalveolar. *Rev Gest & Sau.* 2016; 15(2): 1-6.

Fotobiomodulação e seus benefícios nos protocolos de trauma dental em crianças: relato de caso

Resumo

A classificação das lesões dentárias traumáticas pode envolver dentes, estruturas de suporte ou mucosa gengival e oral. O uso terapêutico de lasers tornou-se prática padrão em muitas áreas médicas, mas a traumatologia dentária ainda não é uma delas. Este relato de caso retrata o traumatismo dentário de uma menina de 36 meses de idade, encaminhada ao Centro de Traumatismo Dentário para Crianças e Adolescentes de uma clínica odontológica universitária (Brasil). A queda da escada em casa resultou em trauma facial, avulsão de incisivo decíduo e lesões em partes moles. A mãe relatou dor e inflamação no lábio dilacerado. Após o exame, um laser de baixa potência foi aplicado no lábio ulcerado e nos tecidos gengivais. O protocolo foi aplicação pontual e contínua a 660nm, 1J/ponto a cada 48 horas. A capacidade de biomodulação do laser de baixa intensidade proporcionou cicatrização tecidual completa após 14 dias de sessões. Ensaio clínico são sugeridos. O tratamento conservador neste caso de lesões graves de partes moles em um bebê mostrou um resultado clinicamente satisfatório. A intervenção mínima também foi importante para minimizar possíveis efeitos colaterais psicológicos da terapia odontológica cirúrgica. Os lasers de baixa intensidade são uma excelente alternativa terapêutica para crianças, devido aos seus efeitos analgésicos/anti-inflamatórios e biomoduladores.

PALAVRAS-CHAVE: Fotobiomodulação; Odontopediatria; Traumatismo Dentário; Lesões dos tecidos moles; Relato de caso.

How to cite this paper

Jesus AMB, Gomes MS, Manieri PR, Lopes RRS, Alves AC. Photobiomodulation and its benefits in the dental trauma protocols for children: a case report. Rev Odontol Bras Central 2023; 32(91): 142-151. DOI: 10.36065/robrac.v32i91.1581