

QUANTITATIVE EVALUATION OF POSTERIOR MANDIBULAR REGION BY CONE BEAM COMPUTERIZED TOMOGRAPHY AS A DONOR SITE FOR AUTOGENOUS BONE GRAFTS

AVALIAÇÃO QUANTITATIVA DA REGIÃO POSTERIOR DE MANDÍBULA POR MEIO DA TOMOGRAFIA COMPUTADORIZADA CONE BEAM COMO ÁREA DOADORA PARA ENXERTOS ÓSSEOS AUTÓGENOS

Autores: Rafaela Rangel ROSA¹; Cássio Vinhadelli RIBEIRO²; Caio Vinícius Bardi MATAI³; Marden Batista GOMES⁴; Simone Maria Ragone GUIMARÃES⁵; João César Guimarães HENRIQUES⁶; Julio Cezar de Melo CASTILHO⁷

1- PhD Student, Department of Diagnosis and Surgery, School of Dentistry, UNESP-Paulista State University, São José dos Campos, São Paulo, Brazil.

2- Master Student, Department of Oral and Maxillofacial Pathology, Federal University of Uberlandia, Uberlandia (MG), Brazil.

3- PhD Student, Department of Diagnosis and Surgery, School of Dentistry, UNESP-Paulista State University, São José dos Campos, São Paulo, Brazil.

4- Private Practice in Juíz de Fora, Minas Gerais, Brazil.

5- PhD Student, Department of Diagnosis and Surgery, School of Dentistry, UNESP-Paulista State University, São José dos Campos, São Paulo, Brazil.

6- Adjunct Professor, Department of Diagnosis, Federal University of Uberlandia, Uberlandia (MG), Brazil.

7- Adjunct Professor, Department of Diagnosis and Surgery, School of Dentistry, UNESP-Paulista State University, São José dos Campos, São Paulo, Brazil.

ABSTRACT

Knowledge of the craniofacial anatomic structures is fundamental for successful autogenous bone grafting surgeries in implant dentistry. In view of the limitations of panoramic radiography, as a bidimensional image, Cone Beam Computerized Tomography (CBCT) has become necessary, as it makes possible to observe potential segments of autogenous bone grafting for implant placement in edentulous regions. The aim of this paper was quantify the bone thickness using CBCT to measure the thickness of the vestibular cortical-medullary bone in the mandibular retromolar and molar regions, as donor segments for the patients. The scans were obtained from a Newtom QVT 9000 3G Aperio® Tomograph. They were taken from mandibles

of 50 patients. We obtained statistically significant differences between measurements of molar areas of men and retromolar area of women ($p < 0.05$). The results of this research broaden the dentist's knowledge about evaluating potential donor areas in the posterior region of the mandible, as regards the requirement of predictability. In conclusion, greater thickness of donor area was observed in both the male and female gender bilaterally, in the mandibular retromolar and third molar regions. Furthermore, upper segment region presented greater cortical thickness in all the studied regions.

KEYWORDS: Computerized tomography; Dental implants; Bone graft.

INTRODUCTION

Knowledge of the craniofacial anatomic structures is fundamental for successful autogenous bone grafting surgeries in implant dentistry. This enables the dental surgeon to perform the osteotomy in the oral cavity with confidence, in order to restore the individual's function, esthetics and health, and to provide the patient with pre-operative information with regard to the extension of surgical resection and clinical assistance^{1,2}.

In view of the limitations of panoramic radiography, as a bidimensional image, Cone Beam Computerized Tomography (CBCT) has become necessary³, as it makes possible to observe potential segments of autogenous bone grafting for implant placement in edentulous regions^{1,3,4}. CBCT does not generate superimposition of bone structures, allowing exactness and precision for identifying anatomic structures such as the inferior alveolar canal, mental foramen, mandibular foramen, vestibular and lingual cortical bone. In CBCT the transaxial slices allow one

to determine the best segment for performing osteotomies in the retromolar region, bearing in mind the proximity relationship of the mandibular canal to the mandibular ramus, without damaging important structures such as the inferior alveolar nerve⁵⁻⁷.

Among the mandible anatomic regions, the retromolar area is an essential intraoral donor segment for autogenous bone grafting mainly due to: relatively easy access to it, smaller surgical area and morbidity; reduction in edema; nature, contour and cortical bone thickness^{1,6}.

The study aim was quantify the bone thickness using CBCT to measure the thickness of the vestibular cortical-medullary bone in the mandibular retromolar and molar regions, as donor segments for the patients.

MATERIAL AND METHODS

Scans were obtained from digital files of a private clinic. They were taken from mandibles of 50 individuals, of whom 29 were

women and 21 men, ranging from 35 to 77 years (mean age X years), indicated for treatment with endosseous oral implants. As exclusion criteria, systemic diseases that affect bone metabolism, e.g. osteoporosis, patients submitted to teeth extractions before 6 months, implants or any other surgery in the evaluated areas were excluded.

The exams were performed in a Newtom QVT 9000 3G Aperio® Tomograph (Verona, Italy). In this study, the images in the tomograph were obtained with a 9 inch small field of view at high resolution, generating transaxial slices with 0.25mm thickness and isotropic voxels (at the time of the research, the available tomograph worked with these voxel parameters), of the mandibular retromolar and molar regions, on the left and right sides of each individual.

In order to guarantee the exams accuracy, the equipment was calibrated daily (in accordance with the manufacturer's protocol) before the exams were performed. Two Radiologists trained and familiarized experienced radiologist, who have knowledge about Implant Viewer program® version 2.608 software (Anne Solutions 2007, São Paulo, SP, Brazil), and followed up all the measurement procedures by both radiologists for intra- and inter-observer measures evaluation.

Implant Viewer was used to the measurements of dentate and partially edentulous individuals, using a 200% magnification. Among all axial images generated from the scan, the central mandibular axial was selected to panoramic reconstruction delimitation. Afterwards, transaxial slices were generated from the panoramic view, and selected the central transaxial slice of the evaluated areas (retromolar, 1st, 2nd and 3rd molars), for the measurements (Fig. 1).

To measure the vestibular bone thickness in the retromolar, first molar (36/46), second molar (37/47) and third molar (38/48) regions, three radiographic anatomic distances (upper segment - "A", middle segment - "B" and bottom segment - "C") were used (Fig. 2). These distances were measured perpendicular to a white line (line 1), that is a reference line which defines the long mandible axis and is tangent to the vestibular cortical portion of the mandible canal (Fig. 1). Specifically, the middle segment and bottom segment distances, were obtained maintaining a surgery safety margin for the mandibular canal delimited by line 2 (a line that starts from the bone ridge intersection with the line 1, ending on the bottom segment inner extremity distance) (Fig. 1).

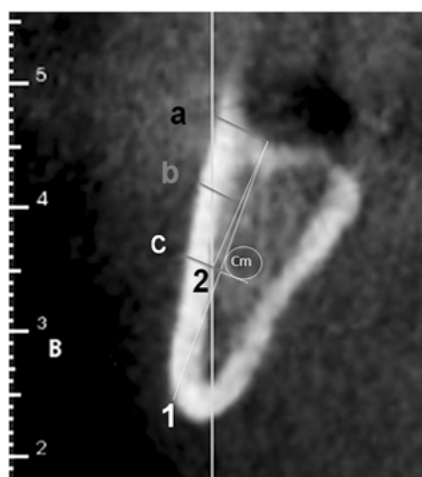


Figure 2 - A) Transaxial slice view and radiographic anatomic upper segment - "A", middle segment - "B" and bottom segment - "C" distances (mm); B) Line 1 - line which defines the long mandible axis and is tangent to the vestibular cortical portion of the mandible canal; C) Line 2 - line from the bone ridge intersection with the line 1, ending on the bottom segment distance inner extremity.

- a. Upper segment distance (A): represented by a line that starts from the bone ridge intersection with the line 1, and continues in a perpendicular direction, until the most buccal external cortical point (Fig. 2);
- b. Middle segment distance (B): represented by a line perpendicular to a line of reference, line 1, equidistant to the upper segment and bottom segment, distances until the line 2 crossing (Fig. 2);
- c. Bottom segment distance (C): represented by a line perpendicular to line 1, tangential to the most inferior mandibular canal portion, starting 2 millimeters from the mandibular canal (safety margin) until the most buccal external cortical point⁵ (Fig. 2).

In addition to this, for partially dentate individuals with presence of some of their mandibular molars on the evaluated sides, the first radiographic anatomic distance measured was that corresponding to the retromolar region in the median transaxial slice. In the dentate regions corresponding to the mandibular first molar (36/46), second molar (37/47) and third molar (38/48), these measurements were not taken because of the difficulty in observing the corticals and lines of reference of the slices. However, the regions with absence of some of these mandibular molars were measured normally.

Whereas for edentulous individuals, the first radiographic anatomic distance measured was that of the vestibular cortical bone passing through the slice parallel to the anterior edge of the mandibular ramus, corresponding to the region posterior to the last mandibular molar, the retromolar region (Fig. 3). Forty transaxial slices (0,25 mm each; 10 mm in total) were considered to characterize the mesio-distal distance of each molar (1st, 2nd and 3rd)⁹. The intraclass correlation coefficient was calculated for the intra and interobserver agreement.

Non parametric tests were used for the comparisons of each measurement (upper segment, middle segment and bottom segment) in each region, between the male and female gender, by means of the Mann-Whitney U test ($\alpha=0.05$), also used for comparing the right and left sides, and the Kruskal-Wallis test ($\alpha=0,05$) for each region. The *post-hoc* test for pair-to-pair comparison was applied in cases in which the H_0 hypothesis was rejected¹⁰. To verify the correlation between the variable age and each of the studied measurements, Spearman's correlation test was applied.

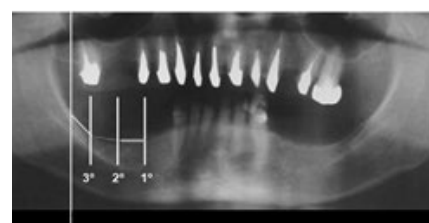


Figure 1 - Panoramic reconstruction showing the selected areas for the measurements (retromolar, 1st, 2nd and 3rd molars) in the generated transaxial slices.

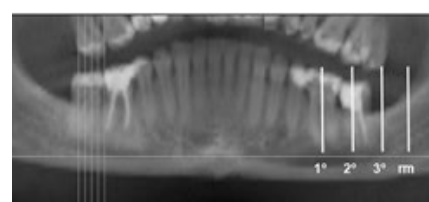


Figure 3 - Example of a panoramic cut and radiographic anatomic distances in the mandibular retromolar (rm) and molar regions, and image of reference of median transaxial cuts.

This project was approved by the Local Ethics Committee on Research involving Human Beings, of the School of Dentistry, São Jose dos Campos - UNESP under Protocol No. 042/2009-PH/CEP.

RESULTS

The intraclass correlation coefficient indicated excellent intraobserver agreement (0.84) and good interobserver agreement (0.73).

Tables 1 to 4 present the descriptive statistics of age and the measurements studied for the male and female genders, as well as the *p*-values for the comparisons between the upper segment, middle segment and bottom segment measurements for each region and the result of the *post-hoc* test.

From the results of the pair-to-pair *post-hoc* comparison, in individuals of the male gender, statistically significant differences were observed between measurement upper segment (A), middle segment (B) and bottom segment (C) in the retromolar region (*p*<0.05) on the right and left sides what explain the bio-type variation (Table 1). The "A" measurement values had the

highest value compared with all the others evaluated regions. In the mandibular third molar region (38/48), in male individuals, statistically significant differences were observed between measurements "A", "B", "C" (*p*<0.05), and again "A" had the highest value, although lower than in the retromolar area (Table 2).

For the female gender, in the retromolar area "A" had the highest value compared with all the others areas. And for mandibular third molars regions, on the right side "C" had the highest value whilst on the left side "B" was the highest mean and a bit higher than "a" mean value. For both male and female gender, the majority measurements in the second and first molar regions had lower values compared with retromolar and third molar regions (Table 3 and 4).

For Spearman's index (*ρ*) and the *p*-value for the correlations between age and the studied measurements for individuals of the male and female genders, the results of the correlation test pointed out little or no correlation between age and the studied measurements, both in individuals of the male and female genders (-0.5<*ρ*<0.5).

Table 1 - Descriptive Statistics of age and of measurements A, B and C for the retromolar region (RS – right side; LS – left side); *p*-values and results of post-hoc test for comparisons between the measurements A, B and C – male and female gender

	AGE (M)	RS (M)			LS (M)			AGE (F)	RS (F)			LS (F)		
		A	B	C	A	B	C		A	B	C	A	B	C
N	29	29	29	29	29	29	29	21	21	21	21	21	21	21
Minimum	35,0	0,0	0,0	0,0	0,0	0,0	0,0	39,0	1,7	1,4	1,0	1,9	1,8	1,2
Mean	55,6	3,8	2,6	2,1	4,0	2,8	1,9	57,5	3,4	2,7	2,0	3,9	3,0	2,1
SD	11,8	1,3	0,8	0,7	1,7	1,1	0,7	9,5	1,0	0,8	0,5	1,3	1,0	0,6
Maximum	77,0	5,9	4,4	3,9	7,0	5,4	3,2	74,0	6,1	4,6	3,5	7,7	6,1	4,0
<i>p</i> -Value		0,00			0,00				0,00			0,00		
Different		B; C	A; C	A; B	B; C	A; C	A		B	A; C	A; B	B; C	A; C	A; B

Table 2 - Descriptive Statistics of age and of measurements f A, B and C or the mandibular 3rd molar region (RS – right side; LS – left side); *p*-values and results of post-hoc test for comparisons between the measurements A, B and C – male and female gender

	AGE (M)	RS (M)			LS (M)			AGE (F)	RS (F)			LS (F)		
		A	B	C	A	B	C		A	B	C	A	B	C
N	29	29	29	29	29	29	29	21	21	21	21	21	21	21
Minimum	35,0	0,0	0,0	0,0	0,0	0,0	0,0	39,0	0,0	0,0	0,0	0,0	0,0	0,0
Mean	55,6	3,3	3,0	1,8	2,9	2,8	1,8	57,5	2,8	2,8	3,0	2,9	3,0	1,9
SD	11,8	2,5	2,1	1,3	2,5	2,2	1,5	9,5	1,8	1,7	2,0	2,0	2,0	1,3
Maximum	77,0	6,9	6,1	5,2	7,4	6,6	5,2	74,0	6,7	6,0	5,7	6,1	5,7	4,6
<i>p</i> -Value		0,000			0,065				0,034			0,041		
Different		C	C	A; B					C	C	A; B	C	C	A; B

Table 3 - Descriptive Statistics of age and of measurements f A, B and C or the mandibular 2nd molar region (RS – right side; LS – left side); *p*-values and results of post-hoc test for comparisons between the measurements– A, B and C male and female gender

	AGE (M)	RS (M)			LS (M)			AGE (F)	RS (F)			LS (F)		
		A	B	C	A	B	C		A	B	C	A	B	C
N	29	29	29	29	29	29	29	21	21	21	21	21	21	21
Minimum	35,0	0,0	0,0	0,0	0,0	0,0	0,0	39,0	0,0	0,0	0,0	0,0	0,0	0,0
Mean	55,6	1,9	1,9	1,2	1,6	2,0	1,4	57,5	2,2	2,4	1,8	2,5	2,7	1,8
SD	11,8	2,3	2,3	1,5	1,8	2,2	1,6	9,5	1,6	1,7	1,3	1,8	1,8	1,2
Maximum	77,0	6,8	5,8	5,3	4,6	6,4	4,6	74,0	5,2	5,8	4,6	5,0	4,8	3,8
<i>p</i> -Value		0,4			0,501				0,277			0,044		
Different		C	C	A; B									C	B

Table 4 - Descriptive Statistics of age and of measurements A, B and C for the mandibular 1st molar region; p-values and results of post-hoc test for comparisons between the measurements A, B and C – male and female gender

	RS (M)			LS (M)			AGE (F)	RS (F)			LS (F)				
	AGE (M)	A	B	C	A	B		C	A	B	C	A	B	C	
N	29	29	29	29	29	29	29	21	21	21	21	21	21	21	
Minimum	35,0	0,0	0,0	0,0	0,0	0,0	0,0	39,0	0,0	0,0	0,0	0,0	0,0	0,0	
Mean	55,6	1,7	1,8	1,2	1,8	2,1	1,3	57,5	2,9	2,9	2,2	2,3	2,5	1,8	
SD	11,8	2,4	2,4	1,8	1,9	2,0	1,2	9,5	1,5	1,2	0,8	1,6	1,5	1,1	
Maximum	77,0	7,5	8,3	7,9	5,9	6,0	3,4	74,0	5,2	4,8	3,5	5,1	4,1	4,1	
p-Value	0,647			0,168			0,062			0,037					
Different	B; C		A; C	A; B	B; C	A; C	A; B				C		B		

DISCUSSION

This study aims to evaluate, by means of CBCT, the cortical medullary thickness in mandibular retromolar and molars donor segments. The previous researches have compared regions similar to those studied in this paper, with regard to intraoral donor segments for autogenous bone grafts, but using conventional radiographs, what definitely is not the most accurate exam^{1,4,5}.

For individuals of the male gender, in some segments, upper segment region had a mean around two times higher than bottom segment region, showing that bone thickness close to the alveolar crest (upper segment region) is a better potential donor when compared with the medullary cortical thickness in the region close to the mandibular canal (bottom segment region). Middle segment measurement presented a mean thickness slightly superior to that of bottom segment region, and a mean value superior to that of upper segment measurement, in the mandibular first molar (36/46) and mandibular second molar (37/47) regions, bilaterally, due to the fact that they are intermediate regions to teeth that have already erupted, which represents a factor that stimulates gain of bone volume for the individual¹.

In individuals of the female gender, in turn, differently from individuals of the male gender, the middle segment mean value was higher on the left side of the mandibular second molar (37/47); bilaterally in the mandibular third molar (38/48) region, and only on the left side of the mandibular first molar (36/46). Nevertheless, the middle segment measurement values in the region of the mandibular third molar (38/48), on the right and of the mandibular first molar (36/46) on the right were practically equal to the values in the regions of the mandibular first molar (36/46) and mandibular second molar (37/47), which are regions that are intermediate to the already erupted teeth. In the same way, it is a factor for bone formation stimulus gain in the individual⁹⁻¹¹.

In this study it was observed that for individuals of both the male and female genders, the region that presented the lowest standard deviation among the upper segment, middle segment and bottom segment measurements was the retromolar region, due to the fact that none of the individuals in the sample presented bone resorptions resulting from tooth loss in the region, since there never was any tooth in this region. Whereas the highest standard deviation for the individuals of both the male and female gender was in the mandibular third molar (38/48) region precisely for the upper segment value (Table 2), which represent the region preferentially chosen for osteotomies, in the case of

surgeries for the removal of these teeth, a factor which explains the reason why the standard deviation was higher than it was in the other regions, since surgeries and osteotomies vary from one individual to another, and so does the age at which an individual was submitted to this type of procedure, a fact similar to the findings in the cited studies¹²⁻¹⁵.

To minimize the risk of injuring the inferior alveolar nerve, linear distances must be considered between the vestibular and superior aspects of the mandibular canal, external vestibular cortical margin and the alveolar crest when planning mandibular osteotomies¹⁷.

As regards the mean thicknesses of the upper segment, middle segment and bottom segment in the first and second molar regions, measurements in the mandibular retromolar, first, second and third molar regions, it was observed that of the 24 comparisons made in 18 situations, individuals of the female gender presented superior bone thickness in comparison with those of the male gender. This suggests that men normally lose their teeth at an earlier stage than women do, and also that women are more concerned about oral health, and therefore, present less need for bone grafts. In addition, greater bone resorption was observed in men, due to more precocious loss of teeth and the possibility of presenting a potential donor segment for bone grafting.

It is important to emphasize that the parameters (0.25 mm voxels) used by this research are not ideal today, considering smaller voxels and lower dosage of radiation employed by the actual tomography apparatus, although the results and conclusions of the research are not altered by this.

The results of this research broaden the dentist’s knowledge about evaluating potential donor areas in the posterior region of the mandible, as regards the requirement of predictability. This favors, facilitates and speeds up planning with regard to selection of the bone graft donor area, without leaving out the guidance obtained by tomographic exams.

CONCLUSION

In conclusion, greater thickness of donor area was observed in both the male and female gender bilaterally, in the mandibular retromolar and third molar regions (38/48). Furthermore, upper segment region presented greater cortical thickness in all the studied regions. In view of the results of this research, the use of CBCT is recommendable for verifying the bone thickness when planning osteotomy in these regions, in order to prevent sensory alterations resulting from neural damage.

CONFLICT OF INTEREST

The authors confirm that this article content has no conflicts of interest.

REFERENCES

01. Greenstein G, Cavallaro J, Tarnow D. Practical application of anatomy for the dental implant surgeon. *J Periodontol.* 2008; 79(10): 1833-46.
02. Flanagan D. A comparison of facial and lingual cortical thicknesses in edentulous maxillary and mandibular sites measured on computerized tomograms. *J Oral Implantol.* 2008; 34(5): 256-58.
03. Angel JS, Mincer HH, Chaudhry J, Scarbez M. Cone-beam computed tomography for analyzing variations in inferior alveolar canal location in adults in relation to age and sex. *J Forensic Sci.* 2011;56(1): 216-19.
04. Hanazawa T, Sano T, Seki K, Okano T. Radiologic measurements of the mandible: a comparison between CT- reformatted and conventional tomographic images. *Clin Oral Impl Res.* 2004; 15(2): 226-32.
05. Tsuji Y, Muto T, Kawakami J, Takeda S. Computed tomographic analysis of the position and course of the mandibular canal: relevance to the sagittal split ramus osteotomy. *Int J Oral Maxillofac Surg.* 2005; 34(3): 243-46.
06. Myamoto I, Tsuboi Y, Wada E, Suwa H, Iizuka T. Influence of cortical bone thickness and implant length on implant stability at the time of surgery- clinical, prospective, biomechanical, and imaging study. *Bone.* 2005; 37(6): 776-80.
07. Katranji A, Misch K, Wang HL. Cortical bone thickness in dentate and edentulous human cadavers. *J Periodontol.* 2007; 78(5): 874-78.
08. Proussaefs P, Lozada J, Kleinman A, Rohrer MD. The use of ramus autogenous block grafts for vertical alveolar ridge augmentation and implant placement: a pilot study. *Int J Oral Maxillofac Implants.* 2002;17(2): 238-48.
09. Kobayashi K, Shimoda S, Nakagawa Y, Yamamoto A. Accuracy in measurement of distance using limited Cone-Beam Computerized Tomography. *Int J Oral Maxillofac Implants.* 2004; 19(2): 228-31.
10. Deguchi T, Nasu M, Murakami K, Yabuuchi T, Kamioka K, Takano-Yamamoto T. Quantitative evaluation of cortical bone thickness with computed tomographic scanning for orthodontic implants. *Am J Orthod Dentofacial Orthop.* 2006; 129(6): 721-27.
11. Ludlow JB, Laster WS, See M, Bailey L Tanya J, Hershey GH. Accuracy of measurements of mandibular anatomy in cone beam computed tomography images. *Oral Surg Oral Med Oral Pathol Oral Radiol Endod.* 2007; 103(4): 534-42.
12. Blomqvist JE, Alberius P, Isaksson S. Sensibility following sagittal split osteotomy in the mandible: a prospective clinical study. *Plast Reconstr Surg.* 1998; 102(2): 325-33.
13. Becktor JP, Rebellato J, Becktor KB, Isaksson S, Vickers PD, Keller EE. Transverse displacement of the proximal segment after bilateral sagittal osteotomy. *J Oral Maxillofac Surg.* 2002; 60(4): 395-402.
14. Yamamoto R, Nakamura A, Ohno K, Michi K. Relationship of the mandibular canal to the lateral cortex of the mandibular ramus as a factor in the development of neurosensory disturbance after bilateral sagittal split osteotomy. *J Oral Maxillofac Surg.* 2002; 60(5): 490-95.
15. Levine MH, Goddard AI, Dodson TB. Inferior alveolar nerve canal position: a clinical and radiographic study. *J Oral Maxillofac Surg.* 2007; 65(3): 470-74.

RESUMO

O conhecimento das estruturas anatômicas craniofaciais é fundamental para o sucesso de cirurgias de enxerto ósseo autógeno em implantodontia. Tendo em vista as limitações da radiografia panorâmica, como uma imagem bidimensional, a tomografia computadorizada Cone Beam (TCCB) tornou-se necessária, uma vez que torna possível observar segmentos ósseos com potencial para serem utilizados como enxertos autógenos para a colocação de implante em regiões desdentados. O objetivo deste estudo foi quantificar a espessura de osso usando TCCB para medir a espessura óssea cortical-medular vestibular nas regiões retromolar e molar inferior, como segmentos de doadores para os pacientes. Os exames foram obtidos a partir de um Newtom QVT 9000 3G Aperio ® Tomograph. Estes foram retirados de mandíbulas

de 50 pacientes. Observamos diferenças estatisticamente significativas entre as medidas de áreas molares de homens e área retromolar das mulheres ($p < 0,05$). Os resultados desta pesquisa ampliam o conhecimento do cirurgião-dentista sobre a avaliação de áreas doadoras potenciais na região posterior da mandíbula, no que diz respeito à exigência de previsibilidade. Em suma, observamos uma maior espessura da área doadora, tanto no sexo masculino quanto no feminino, na retromolar mandibular e na região de terceiros molares. A região do segmento superior apresentou maior espessura cortical em todas as regiões estudadas.

PALAVRAS-CHAVE: Tomografia computadorizada; Implantes dentários; Enxerto ósseo.

CORRESPONDING AUTHOR

João César Guimarães Henriques
Email: joacesarhenriques@yahoo.com.br