

IMMEDIATE IMPLANT IN THE ESTHETIC ZONE: CLINICAL AND CBCT FOLLOW-UP OF PERI-IMPLANT TISSUES

IMPLANTE IMEDIATO EM REGIÃO ESTÉTICA: ACOMPANHAMENTO CLÍNICO E TOMOGRÁFICO DOS TECIDOS PERI-IMPLANTARES

Fernando Vacilotto GOMES¹; Frederico MATTIS²; Paulo BARTH²; Juliana Gonçalves GÖELZER³; Luciano MAYER⁴

1 - Dentist, Oral and Maxillofacial Surgeon and Traumatologist. MSc, Oral and Maxillofacial Trauma and Surgery, Universidade Federal do Rio Grande do Sul, Porto Alegre, Brazil. Student, Implant Dentistry Specialization Course, Associação Gaúcha de Ortodontia (AGOR), Porto Alegre, Brazil.

2 - Dentist. Student, Specialization Course in Implant Dentistry, AGOR, Porto Alegre, Brazil.

3 - Dentist, Dental Implant Surgeon. PhD, Oral and Maxillofacial Trauma and Surgery, Pontifícia Universidade Católica do Rio Grande do Sul (PUCRS), Porto Alegre, RS, Brazil. Professor, Graduate Program in Implant Dentistry, Associação Gaúcha de Ortodontia, Porto Alegre, Brazil.

4 - Dentist, Dental Implant Surgeon. PhD, Oral and Maxillofacial Trauma and Surgery, PUCRS, Porto Alegre, RS, Brazil. Course Coordinator, Specialization Course in Implant Dentistry, AGOR, Porto Alegre, Brazil.

ABSTRACT

Technological advances in implant dentistry have substantially increased the number of rehabilitations of patients with immediate esthetic needs, particularly when the use of removable prosthesis during osseointegration does not meet patient expectations and demands. The placement of dental implants and the adequate immediate provisionalization should ensure high-quality functional and esthetic results and a good prognosis. However, questions remain about whether rehabilitation should be immediate in case of fresh sockets, particularly when

the gingival phenotype is unfavorable. This report describes a clinical case of extraction of teeth #11 and #21, immediate dental implant placement and placement of a provisional using the crown of the natural teeth freshly extracted. Results are compared with findings reported in recent studies, and the ideal treatment to maintain gingival architecture is discussed.

KEYWORDS: Dental implant; Dental esthetics; Dental prosthesis; Cone beam computed tomography.

INTRODUCTION

Dental rehabilitation of patients with immediate esthetic needs in the anterior maxillary region has grown steadily in Implant Dentistry^{1,2}. Particularly when the patient does not accept removable prostheses or does not adapt to them, the placement of a dental implant and adequate provisionalization is an alternative that should follow several criteria: local anatomy should be respected; the provisional should have a good emergence profile and a smooth surface resulting from adequate polishing; attention should be paid to functional performance considering centric and eccentric mandibular movements; and esthetic results should be compatible with the harmony of the patient's smile³⁻⁶.

Bone repair after extraction has been studied to find favorable mid- and long-term solutions that preserve labial bone, which is usually thin. The absence of bone in case of bone resorption may negatively affect gingival architecture⁷⁻¹⁰. Cases that are easily treated, in which the area to be rehabilitated in the dental arch has adequate bone height and width and a favorable gingival phenotype, undoubtedly have more predictable esthetic and functional results². However, questions remain about whether certain cases should be immediately loaded when the socket is fresh after extraction, particularly when the gingival phenotype is unfavorable². These cases reflect the current state of Dentistry,

and patients expect treatments to meet the esthetic needs of gingival harmony using prostheses that harmonize with adjacent teeth in the dental arch¹¹⁻¹⁵.

Before the final prostheses are placed, provisionals should be used to ensure adequate gingival preparation. The crown of the natural teeth may be an option for this stage, particularly because, in addition to smoothness that is very close to that of natural enamel, it has a more harmonious profile because it preserves the anatomy and provides better gingival sealing than the acrylic provisionals conventionally used^{16,17}. Another factor is the preservation of enamel characteristics and the remaining root covered by cementum in the cervical portion of the natural teeth veneers, which have biological characteristics that may adapt more physiologically to the soft tissues of the gingiva than synthetic materials^{1,16,18}.

One of the greatest difficulties in implant placement in the anterior maxilla immediately after extraction is associated with the labial bone plate¹⁹. Ankylosis, hypercementosis, excessive crown destruction and very long and robust tooth roots may generate important surgical difficulties, as their presence often rules out the chance of using any labial bone, which is extremely thin, during surgery¹⁹. This may lead to an unfavorable prognosis, not only because of local darkening and dehiscence that may affect the gingiva, but also, and mainly, because of the possible late

exposure of the abutment². In some cases of major bone fracture, bone grafts are necessary, and the patient has to undergo several surgeries to improve esthetics^{15, 20-22}. In such cases, not even top prosthetic rehabilitation achieves good esthetic results, as the gingival architecture and soft tissue harmony are not preserved².

This study describes a clinical case in which teeth #11 and #21 were extracted, dental implants were immediately placed and loaded with provisionals made of the crowns of the freshly extracted teeth. Radiographs and CBCT were used to follow up results, which are here compared with current findings in the literature and ideal rehabilitation procedures to preserve original gingival architecture.

CASE REPORT

A white 35-year-old ASA I female patient presented with tooth #11 mobility and severe sensitivity of tooth #21. During the first examination, the patient reported that her endodontist referred her to our service (Figure 1).

Her history was carefully examined, and her report revealed that, when she was in her early adolescent years, she suffered dentoalveolar trauma with avulsion of her two maxillary central incisors (tooth #11 and #21). The dentist that treated her at the urgency service at that time repositioned the two teeth and used retention for three weeks. During her examination, the patient produced the written referral from her endodontist, who, after

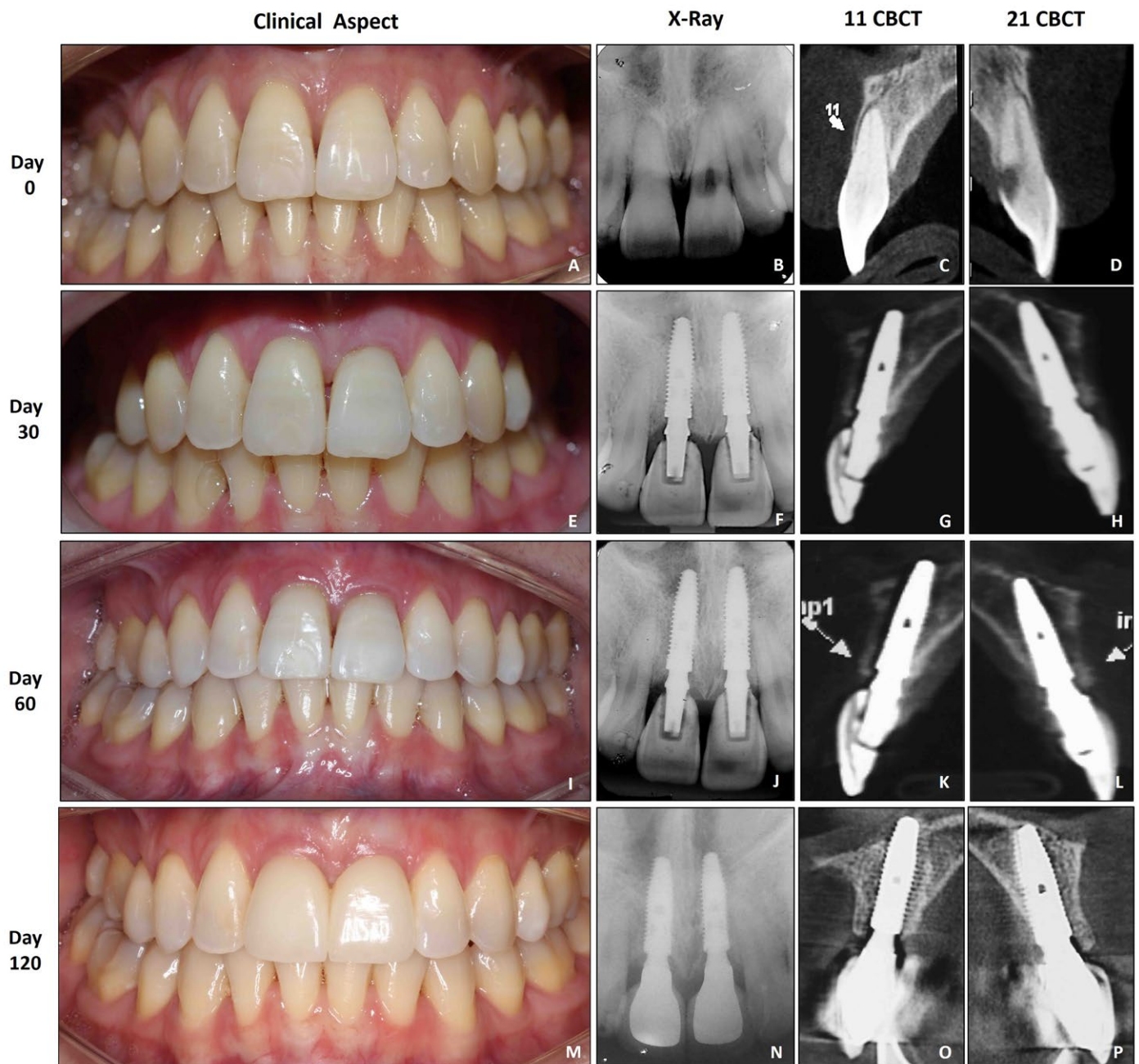


Figure 1 - A, B, C & D) The Initial clinical aspect where the rehabilitative aim by dental implants will occur in teeth #11 and #21 and respectively X-ray and CBCT. Note the quality of the gum tissue and health, as the slender phenotype making it very difficult treatment. **E, F, G, H)** 30 days postoperatively after dental implants installation, the x-ray showing CBCT maintaining the vestibular bone. **I, J, K, L)** 60 postoperative days of dental implants placement. Note, both rx and in CBCT the maintenance of bone tissue. **M, N, O, P)** 90 days postoperatively. The respective radiographic and tomographic examinations have in maintaining the quality of the bone tissue and the line obtained by this technique.

imaging tests and clinical evaluation, concluded that it was impossible to treat tooth #21, because it had no root canals, and #11, because of severe root resorption. Therefore, the treatment plan in our Implant Dentistry service comprised the extraction of teeth #11 and #21, the immediate placement of two dental implants and provisionals prepared using the crowns of the freshly extracted teeth. The patient was surprised at the possibility of preserving esthetic harmony by using her own natural crowns and, therefore, agreed with our treatment plan. Procedures were only performed after the patient understood them and signed an informed consent term.

Infiltration anesthesia was applied to the anterior region of the maxilla for the extraction of teeth #11 and #21. Surgery was planned to cause the least trauma. A periosteal elevator was used carefully to avoid excessive damage to periodontal tissues, and no mucoperiosteal flap was raised. After that, forceps were used to extract teeth #11 and #21 (Figure 2). Immediately after extraction, the socket was irrigated with saline solution, and the walls were carefully examined to check their integrity on all surfaces. Two dental implants were placed according to their three-dimensional positioning, which was determinant to preserve gingival esthetics and the labial bone^{23, 24} (Figure 3). A surgical guide was used to position the implants accurately for the subsequent steps of the prosthetic treatment. After the placement of the dental implants (Cone Morse Alvim, 3.5 x 13mm, Neodent®, Curitiba, Brazil), locking force was greater than 40N/cm² for both implants, and immediate loading was possible. In addition, resonance frequency analysis (RFA) was recorded using an Osstell® transducer (Gothenburg, Sweden), and results were greater than

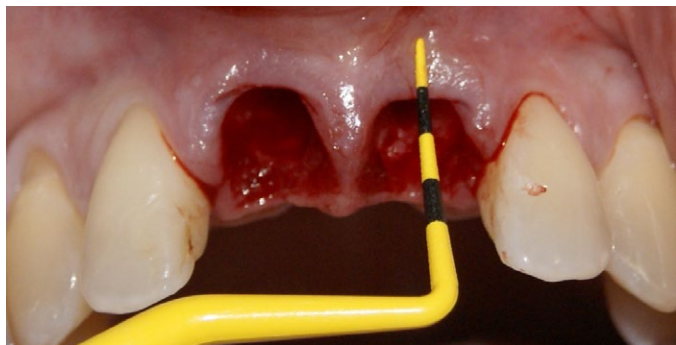


Figure 2 - After the extraction of #11 and #21 elements, the alveoli inspection was performed carefully assessing the remaining buccal bone tissue.

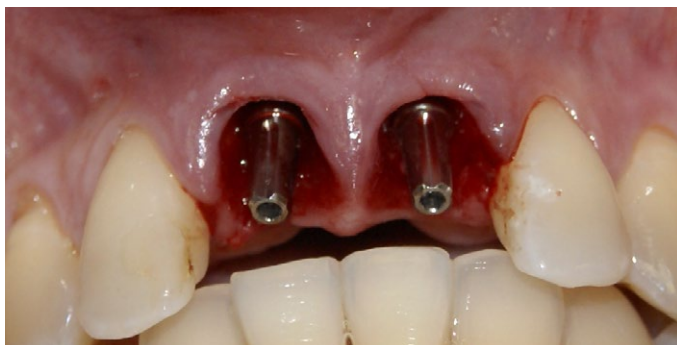

Figure 3 - Dental implants already inserted in the bone tissue by palatal approach in order to maintain the buccal bone. Pillars were installed to conduct immediate provisionalization. Note the quality of tissue obtained after gentle handling of the periodontal tissues.

57 ISQ, which indicated that the amount of contact between bone and implant was good (Figure 4).

Provisionals were prepared for the implants using the coronal portion of the natural teeth #21 and #11, shaping them into two veneers (Figure 5). The two crowns were replaced and fixed over a provisional abutment using light polymerizing resin (Figure 6 and 7). Occlusal adjustments were made in the restoration to ensure that they were free of protusive and lateroprotrusive contacts, which might result in trauma that would complicate osseointegration during the primary peri-implant bone-remodeling phase and might, therefore, lead to implant failure (Figure 8). After that stage and when all adjustments had been made, the bone graft (Bonefill, fine grain, 0.5g, Bionnovation Biomedical, SP, Brazil) was placed in the labial gap (Figure 9). The graft was necessary because the space between implant and bone, when the implant was placed, was greater than 2mm^{8, 10}.

After the clinical treatment was completed, the patient received instructions about hygiene and the maintenance of each prosthetic unit (Figure 10 and 11). A follow-up program of visits every six months was defined. Its purpose was to ensure that the level of satisfaction achieved was maintained for the longest possible time. A control CBCT imaging study every 30 days was planned to evaluate the preservation of peri-implant bone.

DISCUSSION

Restorations using prostheses over implants in the esthetic region and preserving gingival architecture in harmony with adjacent tissues is one of the great challenges in current Implant Dentistry. Esthetic peri-implant results may be more accurately

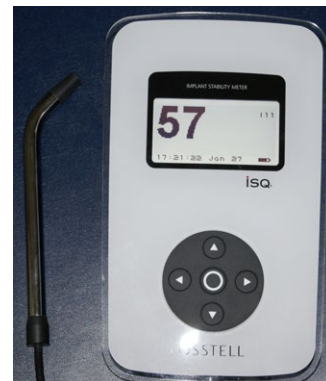

Figure 4 - ISQ value obtained through the resonance frequency analysis (Osstell®) device, where the value was 57 ISQ, allowing the realization of immediate loading on the newly installed dental implants.

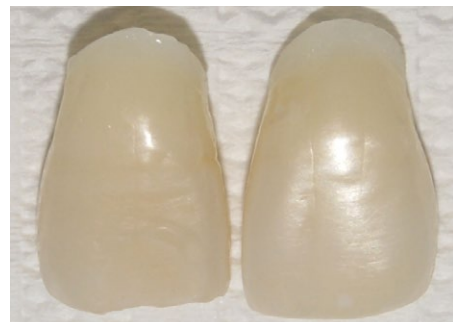

Figure 5 - #11 and #21 natural teeth veneers were cautiously made from palatine faces worn in high rotation turbine of newly extracted elements for provisionalization.

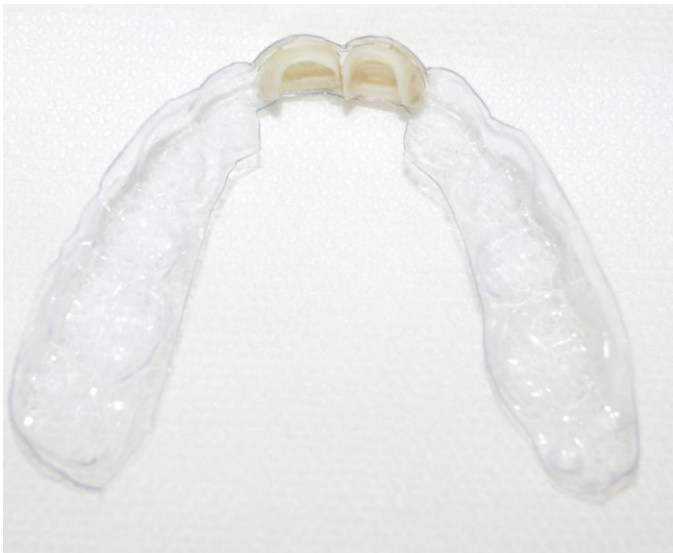

Figure 6 - The surgical guide with facets aspect of prior to mouth placement. Note the adaptation and ease of placement that this technique provides, allowing reproduction of the teeth initial position.

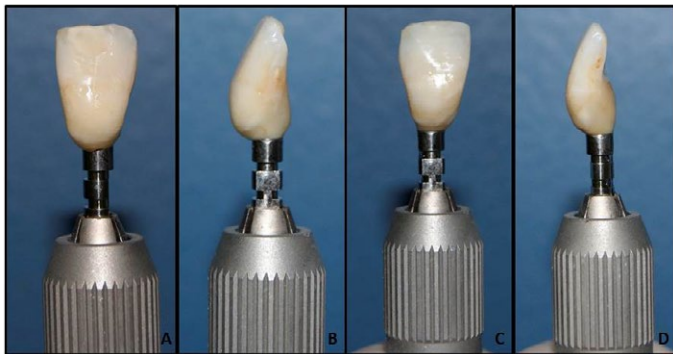


Figure 7 - (A) Buccal appearance of the tooth #11 (B) Medial appearance of the tooth #11. (C) Buccal appearance of the tooth #21 (D) Medial appearance of the tooth #21. Note the quality of the resin and polishing of the facet, which will allow proper adjustment and passive soft tissue and possible long-term quality.

predicted using a diagnostic protocol with five keys that may be evaluated and used for decisions. This protocol includes: (I) relative tooth position, (II) form of periodontium, (III) biotype of periodontium, (IV) tooth form and (V) bone crest position]. In the case described here, for example, the gingival phenotype was extremely thin and unfavorable if not carefully handled, as there was the chance of retraction, implant transparency or visibility of prosthetic abutments through the tissues. This was thoroughly evaluated together with the patient, who was told about all treatment biases, as well as about the necessary hygiene and care that should be observed to preserve the prosthesis.

A surgical guide was carefully planned and manufactured before the surgery to position the implants correctly^{1,3}. Provisional restorations should be accurately placed in the initial position, which may be achieved by using this guide. In our case, it ensured that provisionals were placed at the exact place where the natural teeth were. After the placement of the dental implants, the veneers manufactured from the natural permanent teeth were placed over the implant abutments that fit the initial and final positions, according to the guide. Therefore, the gingival architecture was preserved by using the crown of the freshly

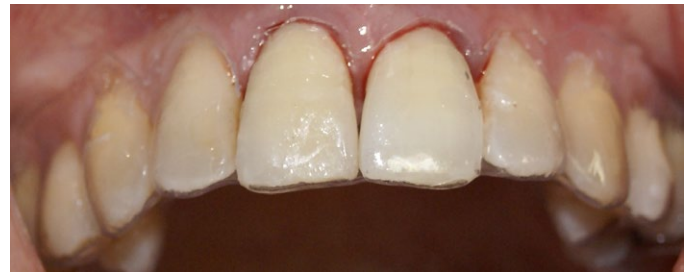

Figure 8 - Surgical guide repositioning with the natural tooth #11 and #21 element facets aiming to be the best location for the provisional realization, keeping the gingival tissues in the same initial condition facilitating their repair.

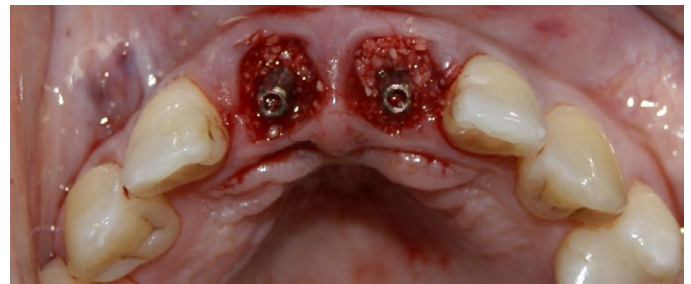


Figure 9 - Immediately postoperatively placement of biomaterial-based on lyophilized bone in the buccal gap region between the implant and bone. This technique aims to maintain buccal bone long-term preservation, preventing their reabsorption.

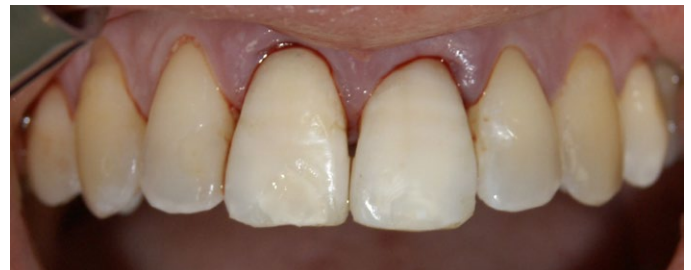

Figure 10 - Immediately postoperative after provisional cementation where we managed to maintain the original contour gum tissue and the aesthetic quality desired by the patient.

extracted tooth, and the soft tissue architecture, enamel smoothness and tooth contour were preserved, which promoted healing and other biological processes^{2,7,9}.

Several studies in the literature demonstrated the possibilities of preserving buccal bone height and discussed the known bundle-bone resorption when the biological criteria are not met after extraction⁷⁻⁹. In the same way, these criteria should be met when implants are placed, particularly in the esthetic region, where hard and soft tissues should be handled very carefully. In the first 6 to 12 months after extraction, buccal bone resorption is progressive if no bone regeneration procedure is adopted, even when there is no excessive trauma during surgery^{7,8}. For that purpose, autogenous, allogeneic or heterogenous bone grafts are available, and scientific findings confirm that esthetic preservation is more effective and prognoses are more predictable when they are used. In the case described here, as in recent studies in the literature, a bone graft was placed in the labial gap (>2 mm) using biomaterial composed of inorganic fine-grained bovine bone to preserve gingival contour in the long term. In the first six months after surgery, the preserved gingival architecture and the healthy aspect of the soft tissue was even better than

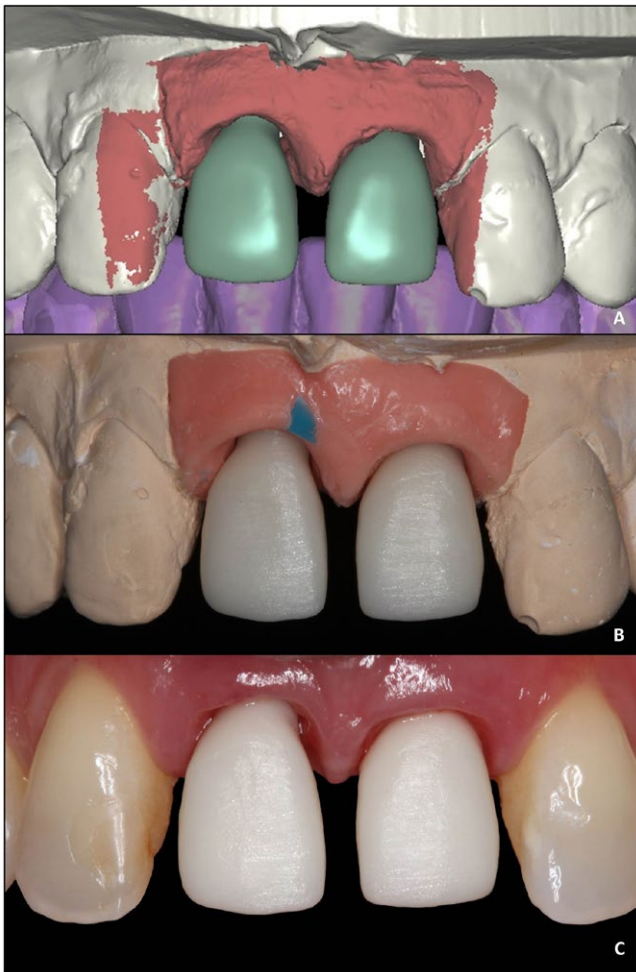

Figure 11 - Copping Zirconia comparison on dental implants # 11 and # 21 region - (A) scanning the plaster model virtually performed (NEODENT® Curitiba, Brazil), as well as making the virtual structure of the zirconia abutment; (B) cappings on the actual plaster model (B); proved mouth (C). Note the quality of the adaptation and the similarity among the three situations showing great reliability of the technique.

before surgery. Moreover, preserved gingival health and the correct and natural three-dimensional positioning of peri-implant tissues were confirmed during monthly follow-up visits^{15,19, 21-25}.

In implant-supported restorations in the esthetic zone after extractions, immediate provisionalizations should be recommended so that the gingival architecture is preserved, as long as all criteria for initial implant stability and occlusal adjustment of the provisional restoration are met¹. Moreover, when the crown of the freshly extracted tooth is used, the manufacture of a provisional restoration seems to promote the preservation of the quality of inserted gingiva. In the case described here, particularly in the first months of bone and gingival repair, the quality of peri-implant tissue repair may be assigned to biological characteristics of enamel and cementum remaining on the surface of the natural veneers of the crown used as a provisional. The contact between enamel and cementum of the provisional restoration with the gingiva may promote better adaptation and tissue response to healing, in contrast with the more porous surface of the type of acrylic used to manufacture provisionals over implants. Despite the quality of the dental tissue remaining in the veneer, the rest of the provisional was carefully manufactured using bis-acrylic resin, which ensured high quality polishing and smoothness and facilitated the adaptation of all peri-implant system^{3, 4, 6, 12, 18}.

CONCLUSION

This study described a clinical case in which the immediate placement of implants after extraction and provisionalization of anterior maxillary teeth using the natural crown of the freshly extracted teeth promoted the preservation of gingival architecture and ensured high-quality esthetics of mid- and long-term results.

ACKNOWLEDGEMENTS

The authors declare that they did not receive any support from private companies or governments.

CONFLICT OF INTERESTS

The authors declare that there is no conflict of interests regarding the publication of this paper.

REFERENCES

- Gomes FV, Volkart FB, Mayer L. Immediate loading in the anterior region using the lost clinical crown natural tooth: a case report. *Dental Press Implantol.* 2012; 6(4): 46-54.
- Kois JC. Predictable single-tooth peri-implant esthetics: five diagnostic keys. *Compendium.* 2004; 25(11): 585-592.
- Cooper LF, Reside G, Raes F, Garriga JS, Tarrida LG, Wiltfang J, Kern M, Bruyn HD. Immediate provisionalization of dental implants in grafted alveolar ridges in the esthetic zone: a 5-year evaluation. *Int J Periodontics Restorative Dent.* 2014; 34(4): 477-86.
- Chrcanovic BR, Albrektsson T, Wennerberg A. Immediate nonfunctional versus immediate functional loading and dental implant failure rates: a systematic review and meta-analysis. *J Dent.* 2014; 42(9): 1052-1059.
- Vervaeke S, Collaert B, Cosyn J, De Bruyn H. A 9-Year Prospective Case Series Using Multivariate Analyses to Identify Predictors of Early and Late Peri-Implant Bone Loss. *Clin Implant Dent Relat Res.* 2014. [Epub ahead of print].
- Spin-Neto R, Pontes AE, Wenzel A, Sakakura CE. Patient Discomfort Following Single-Tooth Implant Placement: A Randomized Controlled Trial of Immediate vs. Conventional Tooth Restoration. *Oral Health Dent Manag.* 2014; 13(2): 441-445.
- Araújo MG, Lindhe J. Dimensional ridge alterations following tooth extraction. An experimental study in the dog. *J Clin Periodontol.* 2005; 32(2): 212-218.
- Araújo MG, Sukekava F, Wennström JL, Lindhe J. Ridge alterations following implant placement in fresh extraction sockets: an experimental study in the dog. *J Clin Periodontol.* 2005; 32(6): 645-52.
- Araújo MG, Sukekava F, Wennström JL, Lindhe J. Tissue modeling following implant placement in fresh extraction sockets. *Clin Oral Implants Res.* 2006; 17(6): 615-624.
- Araújo MG, da Silva JC, de Mendonça AF, Lindhe J. Ridge alterations following grafting of fresh extraction sockets in man. A randomized clinical trial. *Clin Oral Implants Res.* 2015; 26(4): 407-412.
- Mounir M, Beheiri G, El-Beialy W. Assessment of marginal bone loss using full thickness versus partial thickness flaps for alveolar ridge splitting and immediate implant placement in the anterior maxilla. *Int J Oral Maxillofac Surg.* 2014; 43(11): 1373-1380.
- Luongo G, Lenzi C, Raes F, Eccellente T, Ortolani M, Mangano C. Immediate functional loading of single implants: A 1-year interim report of a 5-year prospective multicentre study. *Eur J Oral Implantol.* 2014; 7(2): 187-199.

13. Arruda T, Sukekava F, de Souza AB, Rasmusson L, Araújo MG. Early healing in alveolar sockets grafted with titanium granules. An experimental study in a dog model. *J Biomed Mater Res A*. 2013; 101(7): 1971-1976.
14. Hämmerle CH, Araújo MG, Simion M; Osteology Consensus Group 2011. Evidence-based knowledge on the biology and treatment of extraction sockets. *Clin Oral Implants Res*. 2012; 23(5): 80-82.
15. Araújo MG, Lindhe J. Socket grafting with the use of autologous bone: an experimental study in the dog. *Clin Oral Implants Res*. 2011; 22(1): 9-13.
16. Slagter KW, den Hartog L, Bakker NA, Vissink A, Meijer HJ, Raghoobar GM. Immediate placement of dental implants in the esthetic zone: a systematic review and pooled analysis. *J Periodontol*. 2014; 85(7): e241-250.
17. Chambrone L, Sukekava F, Araújo MG, Pustiglioni FE, Chambrone LA, Lima LA. Root-coverage procedures for the treatment of localized recession-type defects: a Cochrane systematic review. *J Periodontol*. 2010; 81(4): 452-478.
18. Vinnakota DN, Akula SR, Krishna Reddy VV, Sankar VV. A staged approach of implant placement in immediate extraction sockets for preservation of peri-implant soft and hard tissue. *J Indian Soc Periodontol*. 2014; 18(2): 267-271.
19. Araújo MG, Lindhe J. Ridge alterations following tooth extraction with and without flap elevation: an experimental study in the dog. *Clin Oral Implants Res*. 2009; 20(6): 545-549.
20. Araújo MG, Liljenberg B, Lindhe J. beta-Tricalcium phosphate in the early phase of socket healing: an experimental study in the dog. *Clin Oral Implants Res*. 2010; 21(4): 445-454.
21. Araújo MG, Liljenberg B, Lindhe J. Dynamics of Bio-Oss Collagen incorporation in fresh extraction wounds: an experimental study in the dog. *Clin Oral Implants Res*. 2010; 21(1): 55-64.
22. Araújo M, Linder E, Wennström J, Lindhe J. The influence of Bio-Oss Collagen on healing of an extraction socket: an experimental study in the dog. *Int J Periodontics Restorative Dent*. 2008; 28(2): 123-135.
23. Phillips K, Kois JC. Aesthetic peri-implant site development. The restorative connection. *Dent Clin North Am*. 1998; 42(1): 57-70.
24. Tarnow DP. The evolution of periodontal/implant treatment. *Pract Periodontics Aesthet Dent*. 2000; 12(1): 62.
25. Araújo MG, Linder E, Lindhe J. Bio-Oss collagen in the buccal gap at immediate implants: a 6-month study in the dog. *Clin Oral Implants Res*. 2011; 22(1): 1-8.

RESUMO

Os avanços tecnológicos na Implantodontia fizeram com que as reabilitações de pacientes com necessidade estética imediata tivessem um crescimento exponencial nos últimos anos, especialmente em situações onde a utilização de restaurações protéticas removíveis durante o período de osseointegração não contemplam o nível de exigência e a expectativa do paciente. A instalação de um implante osseointegrável e a sua adequada provisionalização imediata devem ser feitas com elevada qualidade a fim de se colaborar com as questões funcionais e estéticas para um bom prognóstico. Todavia, questionamentos se estabelecem no momento em que a resolução imediata do caso deva ser feita

em alvéolo fresco pós-exodontia, especialmente em situações de fenótipo gengival desfavorável. Assim sendo, este artigo tem por objetivo apresentar um caso clínico onde se realizou a exodontia dos dentes 11 e 21, a inserção imediata de implantes osseointegráveis e a provisionalização com a coroa dos dentes naturais recém-extraídos, comparando com a literatura atual, a condição ideal de reabilitação desses casos para manutenção da arquitetura gengival inicial.

PALAVRAS-CHAVE: Implante Dentário; Estética Dentária; Prótese Dentária; Tomografia Computadorizada de Feixe Cônico.

CORRESPONDING AUTHOR

Dr. Fernando Vacilotto Gomes, DDS, MSc.
Rua Felipe Neri, 296/403 – Auxiliadora
90440-150, Porto Alegre, RS, Brazil
Tel.: +55 51 3388.8452 / Fax: +55 51 3388.7363
E-mail: fernandovg2005@yahoo.com.br